

Difficultés et pièges de la mise en place d'une prothèse unicompartmentale (médial et latéral)

E. SERVIEN, S LUSTIG

Croix-Rousse Hospital,
Department of orthopaedic surgery
FIFA medical center of excellence - Lyon University (France)


DIU 2018

INTRODUCTION


- n'est pas une hémi-PTG
- est l'art du "possible"
- est une chirurgie "MIS" mais n'est pas anodine
- n'est pas une intervention Pre PTG
- Permet souvent d'obtenir un genou oublié

Intérêt nouveau

- abord moins invasif
- morbidité inférieure
- rétablissement plus rapide du patient
- très bon résultat fonctionnel



1991



1995

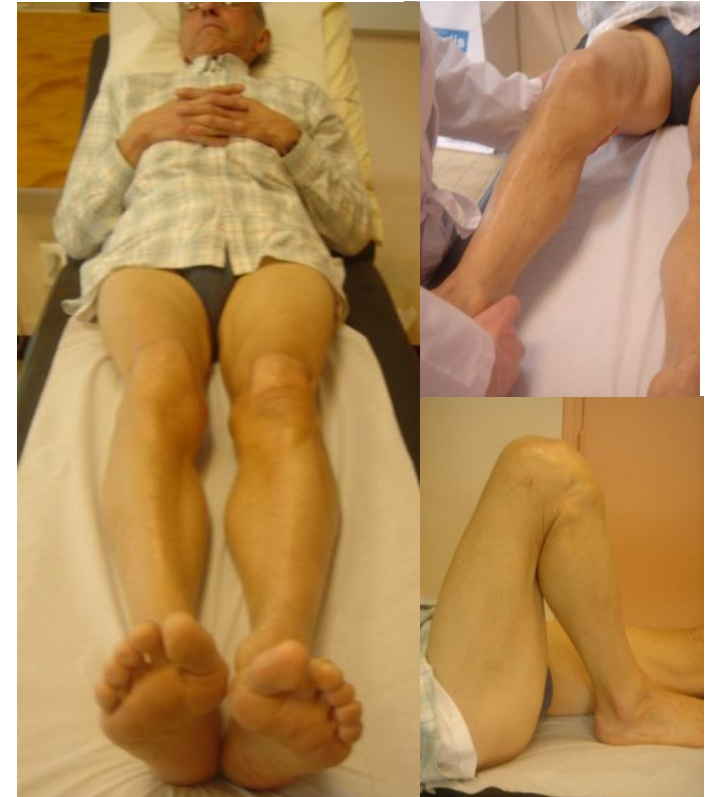“Candidat idéal”

Examen clinique

- DI au niveau interligne
- Amplitudes articulaires complètes
- Pas d'atteinte inflammatoire
- Testing ligamentaire Nal
- Réductibilité de la déformation
- 65 ans et plus
- Non Obèse

J. Rand – Ph. Neyret

ISAKOS Meeting on
“Management of Osteoarthritis of the Knee
Prior to Total Knee Replacement”
Napa California, March 2004

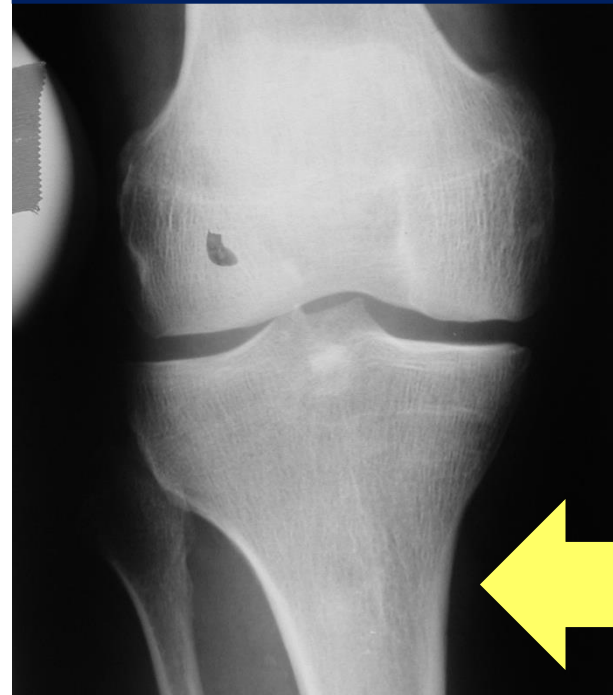
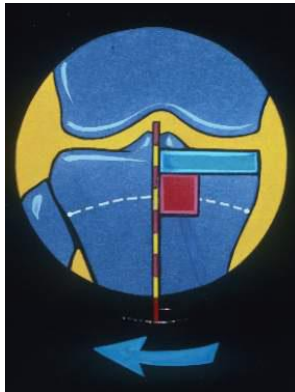


“Candidat idéal”

Radiological check-up

J. Rand – Ph. Neyret
ISAKOS Meeting on
“Management of Osteoarthritis of the Knee
Prior to Total Knee Replacement”
Napa California, March 2004

- Bonne réductibilité
- Complète mais...
- Pas d’hypercorrection



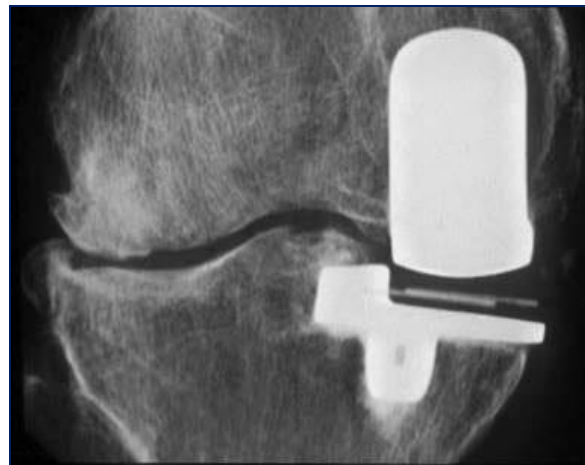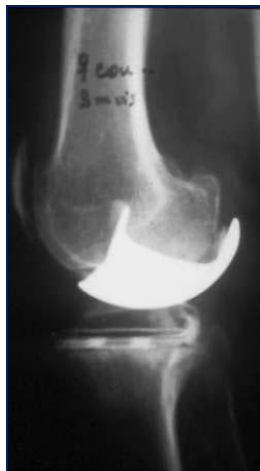Contre indications

Arthrites inflammatoires (chondrocalcinose)

Atteintes pluricompartimentales

Incompétences ligamentaires

- Laxité antérieure
- “Vraie” laxité interne



Limitations

Arthrose fémoro-patellaire

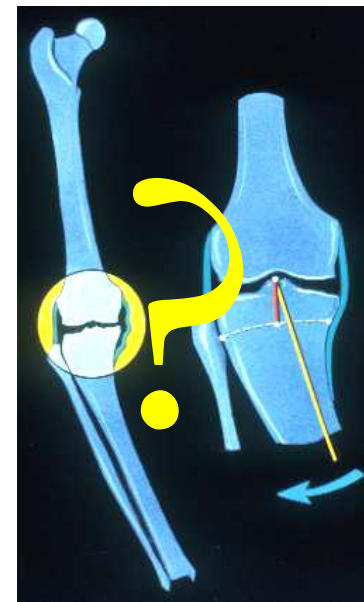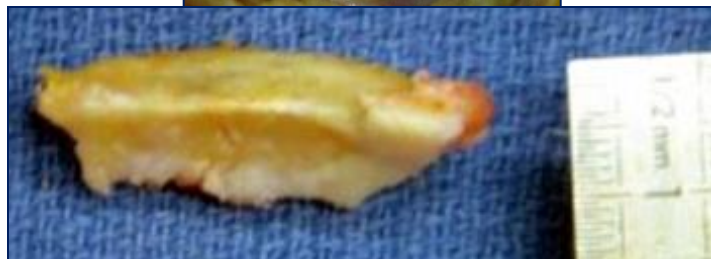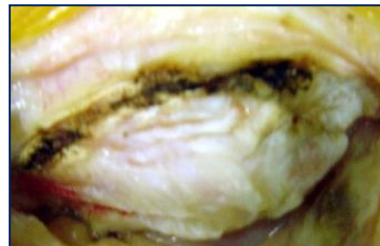?

Flexion < 100°

?

Déformation résiduelle sur les Xr en stress

?



Limitations

Arthrose fémoro-patellaire

?

Flexion < 100°

?

Déformation résiduelle sur les Xr en stress

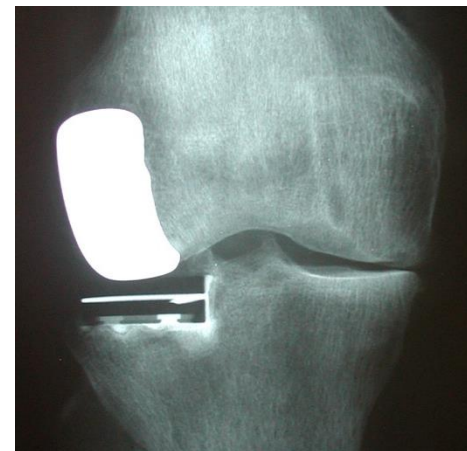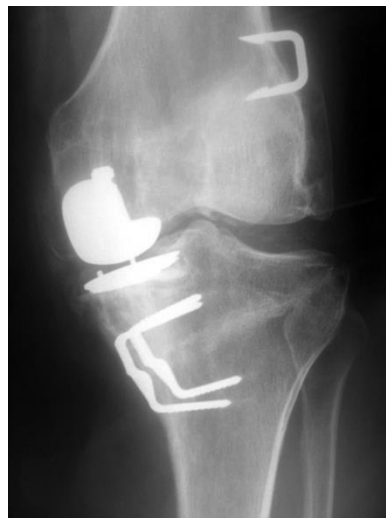?

Après une Ostéotomie

?

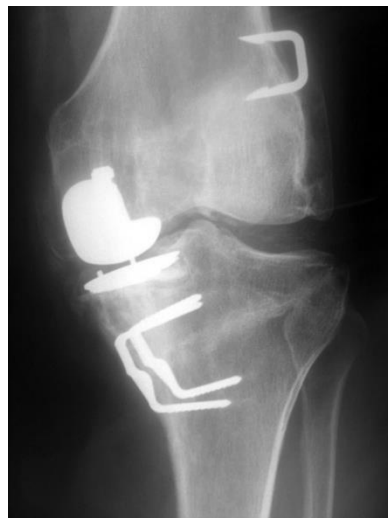Après une Uni

?



Limitations

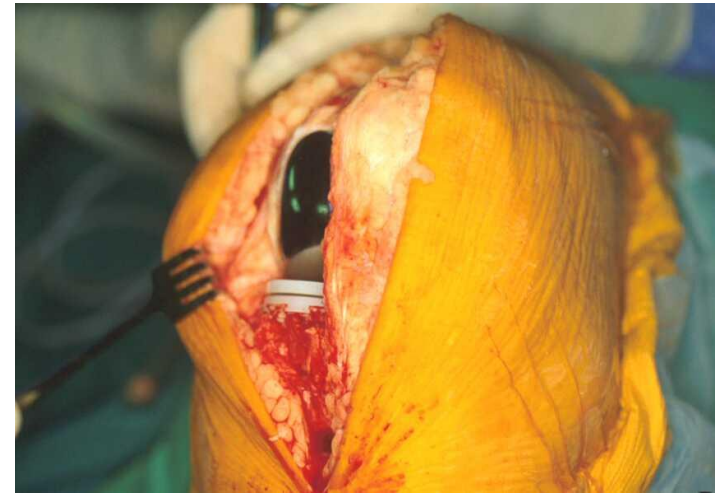
Arthrose fémoro-patellaire	?
Flexion < 100°	?
Déformation résiduelle sur les Xr en stress	?
Après une Ostéotomie	?
Après une Uni	?



TECHNIQUE CHIRURGICALE

- Chirurgien expérimenté :
- Hypocorrection

➔ « On ne change pas l'axe de la jambe »

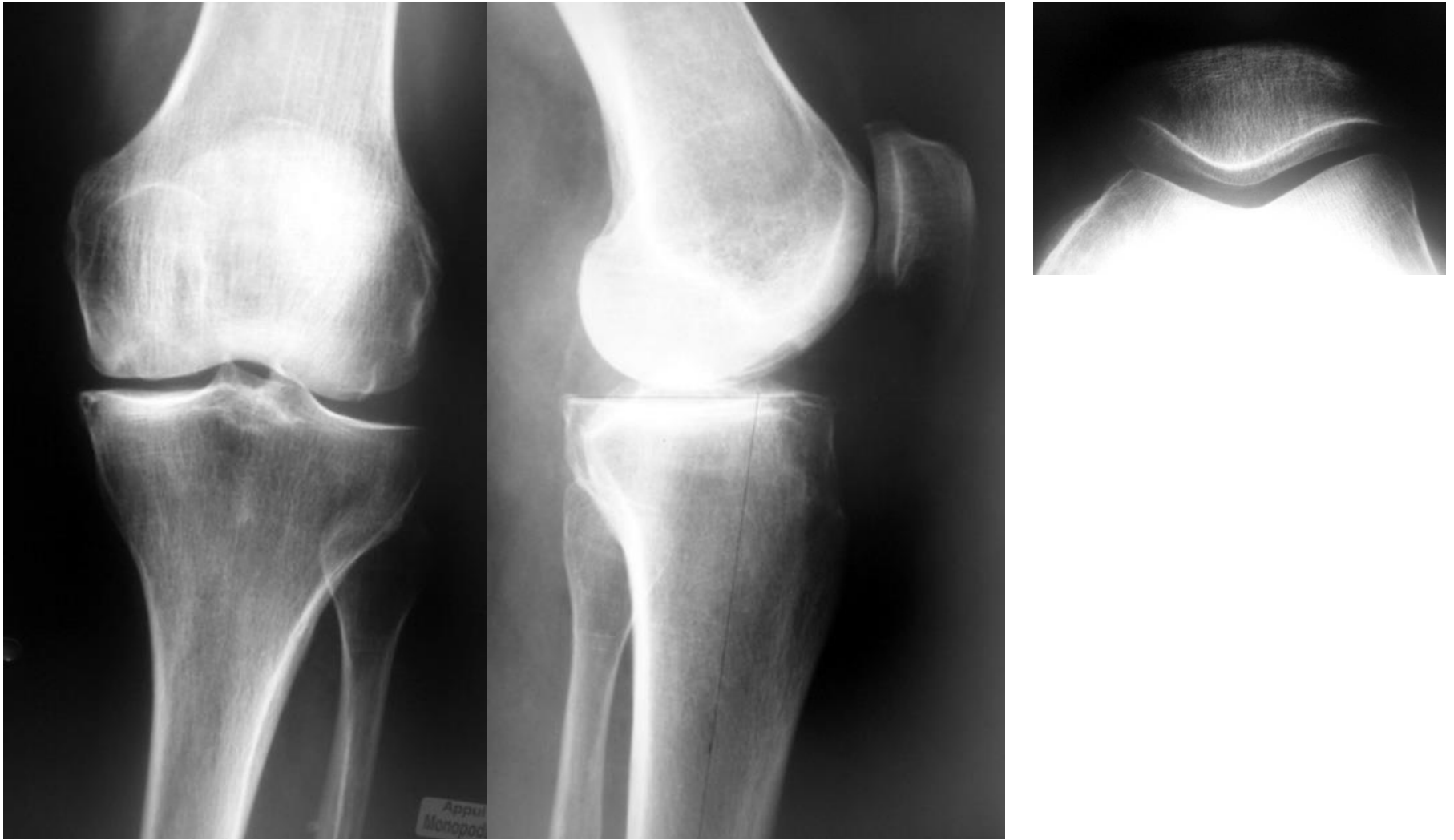

Mrs Bou., 75 Y.

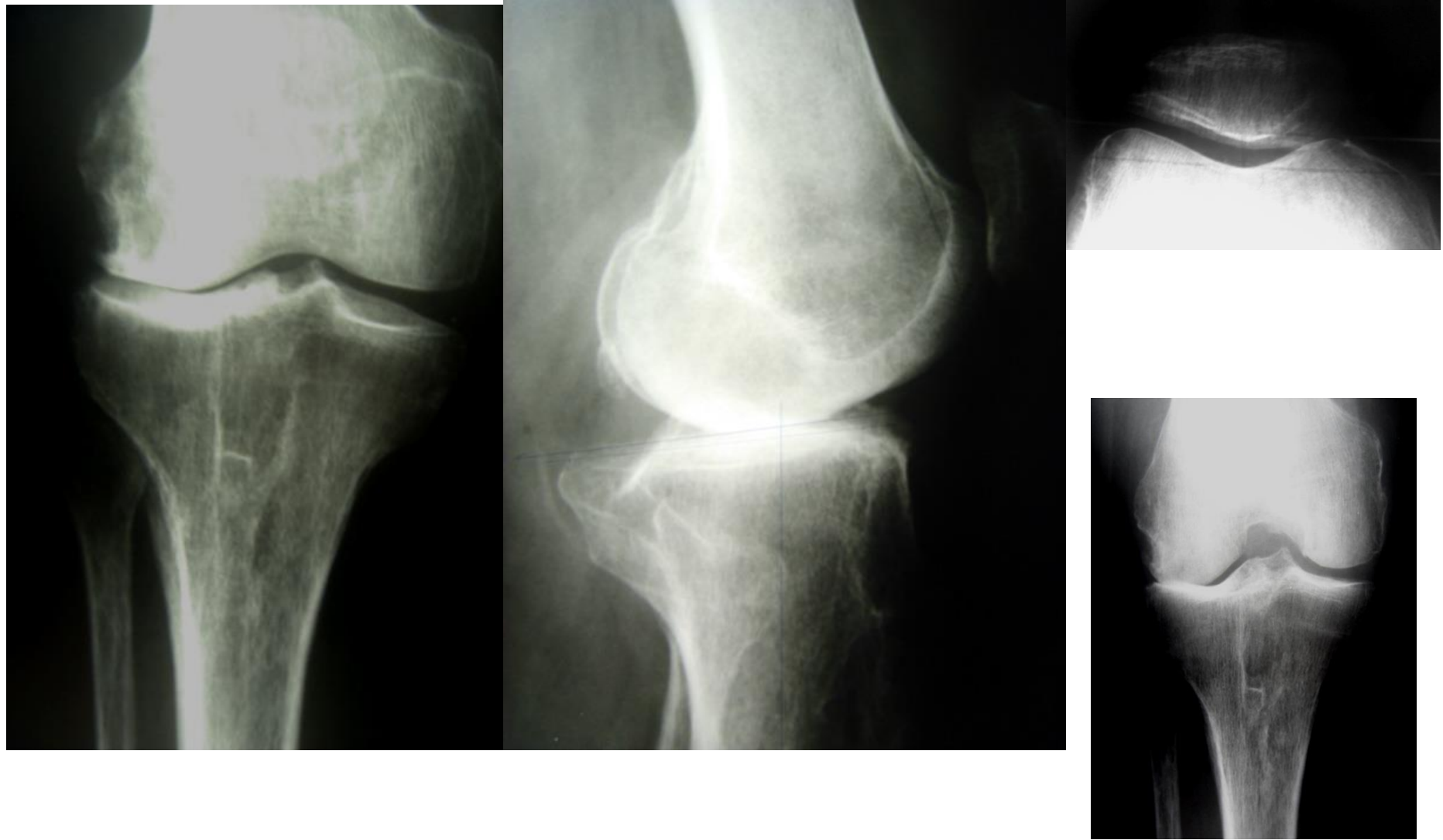
- Medial Uni Left Knee

Mrs Bla, 84 Y.

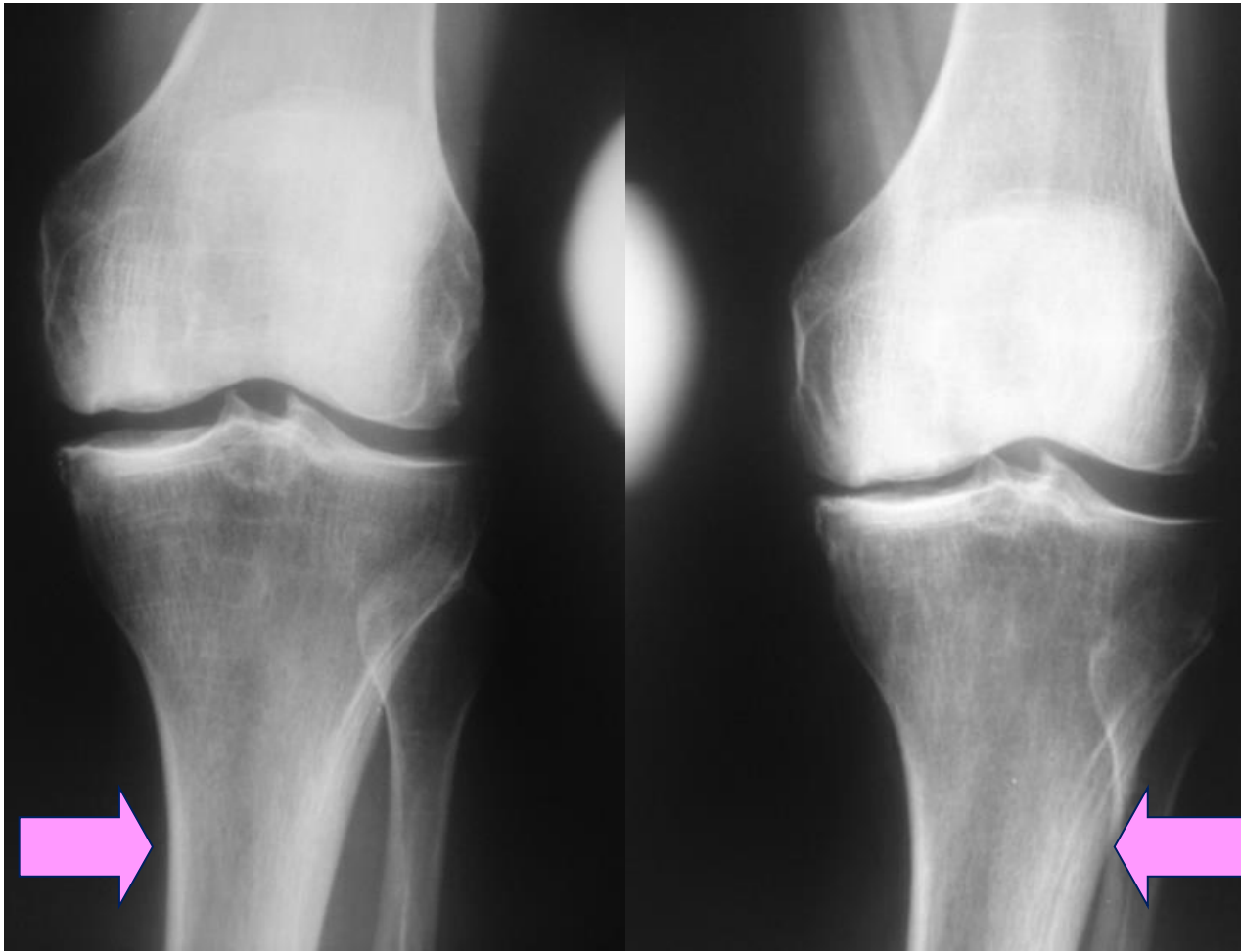- Lateral Uni Right Knee



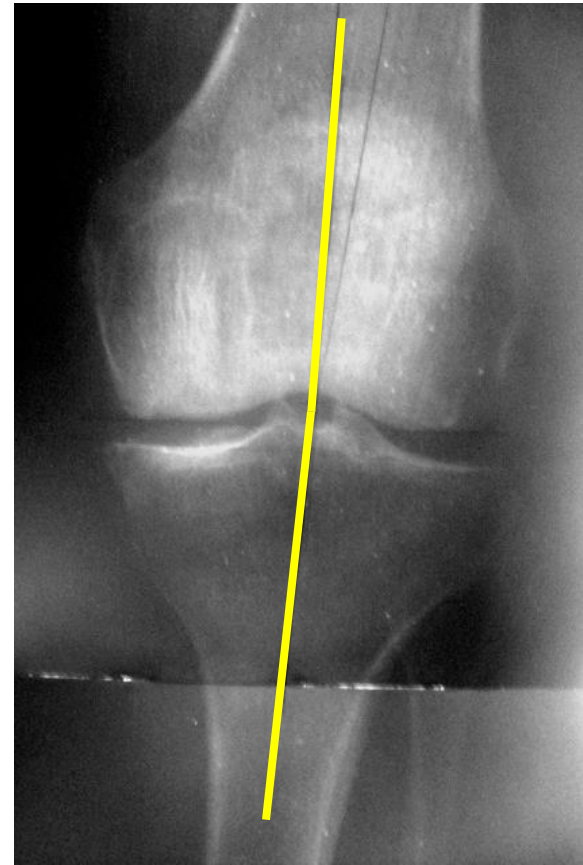
X-rays during the first clinical examination



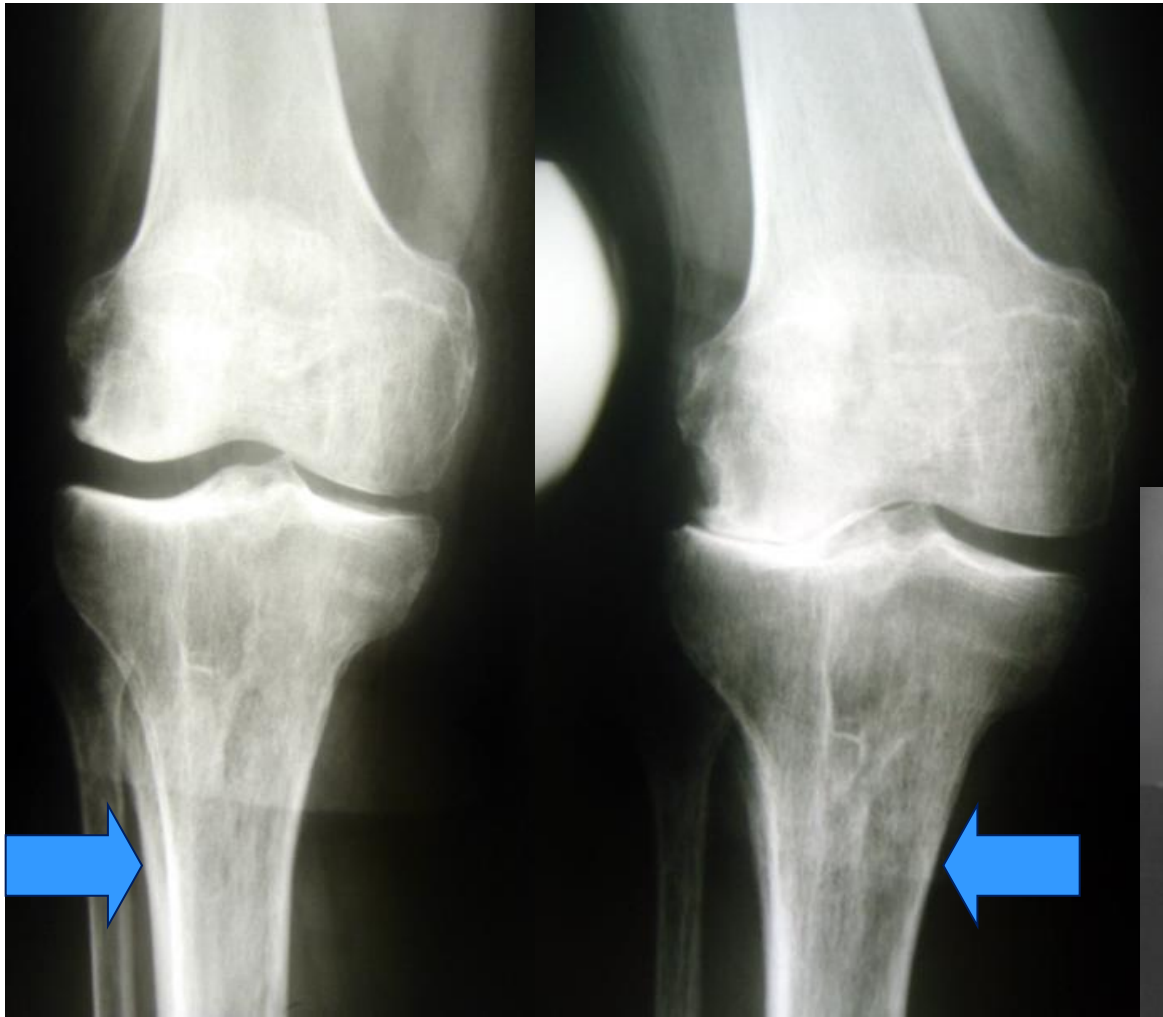X-rays during the first clinical examination



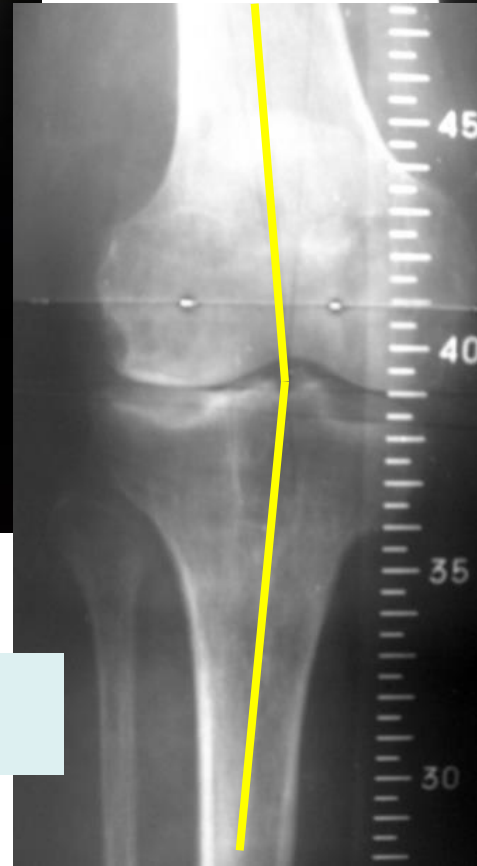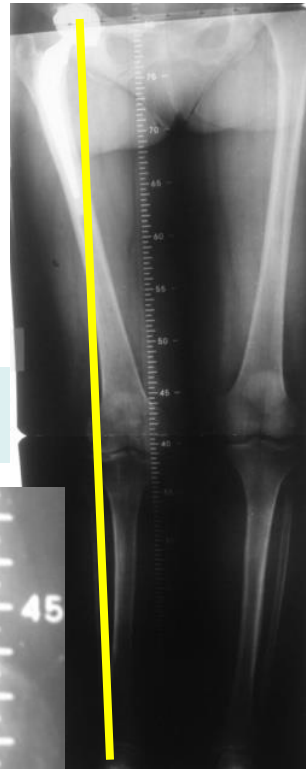Long leg film



X-rays: Preoperative check-up



Long leg film



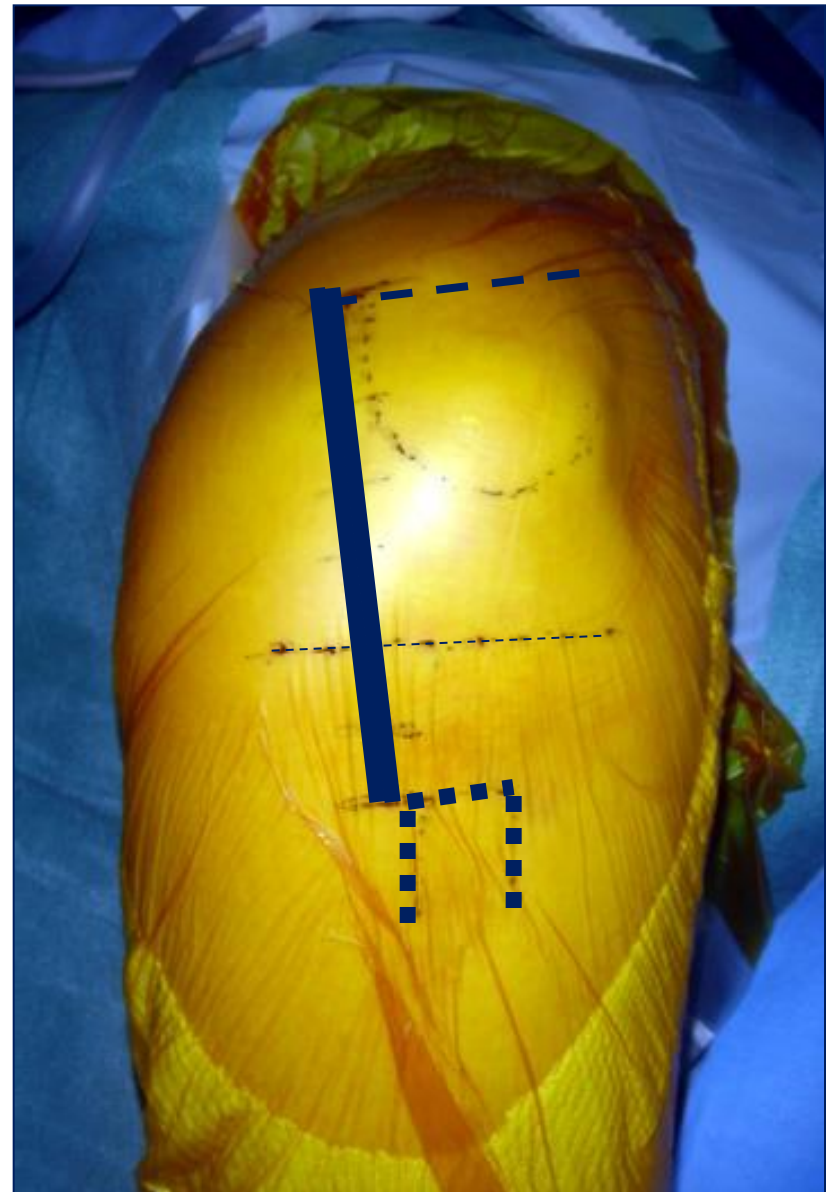
X-rays: Preoperative check-up

Surgical Technique

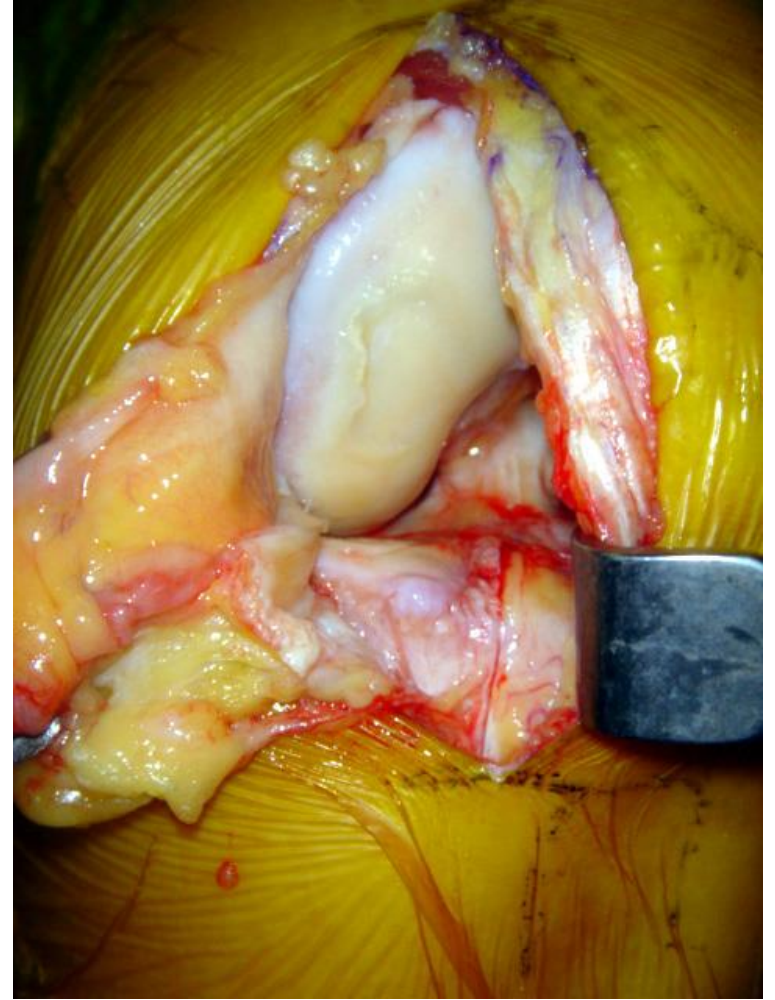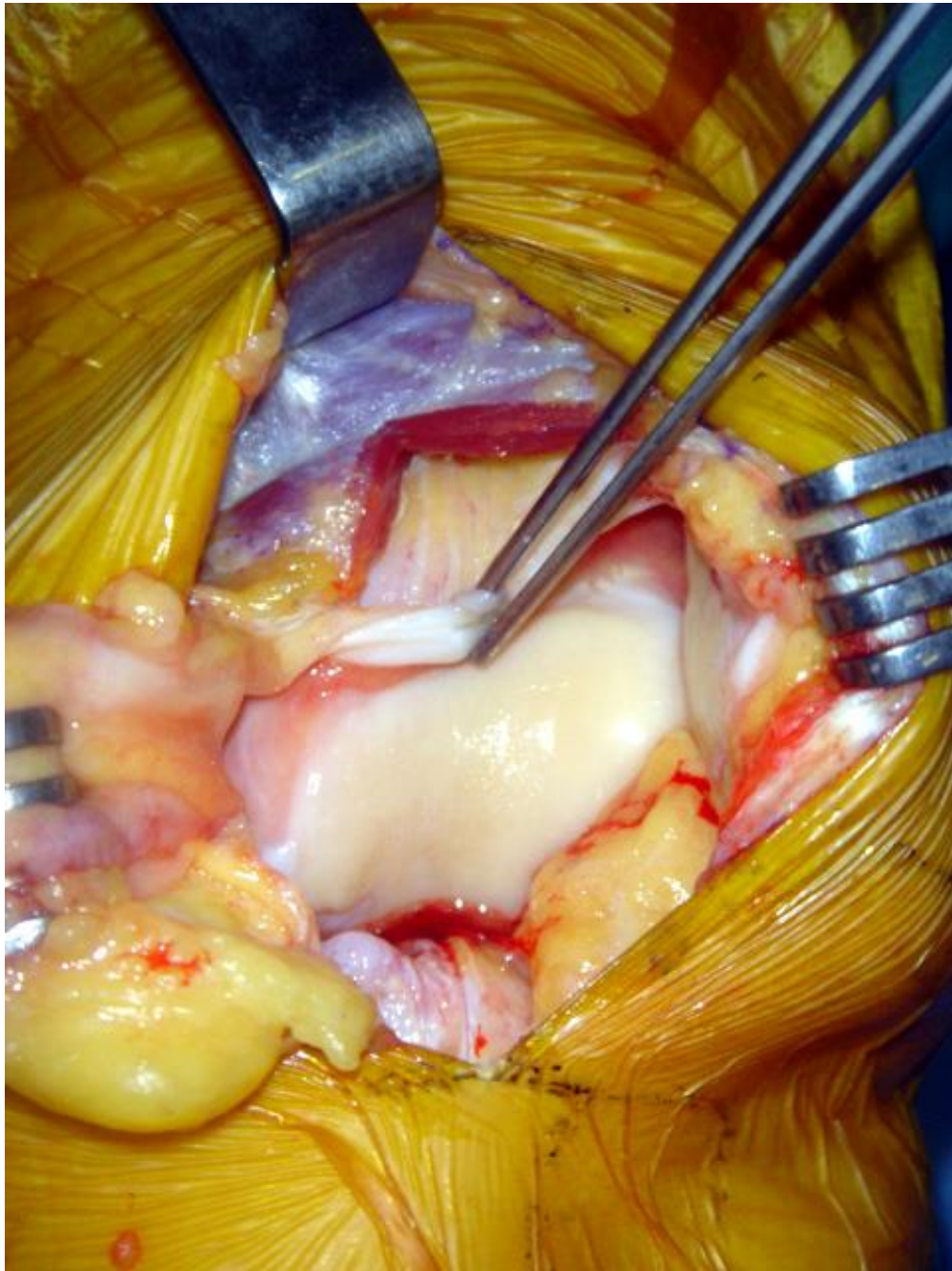
1. Approach
2. Tibial cut
3. Femoral cut
4. Trials
5. Fixation

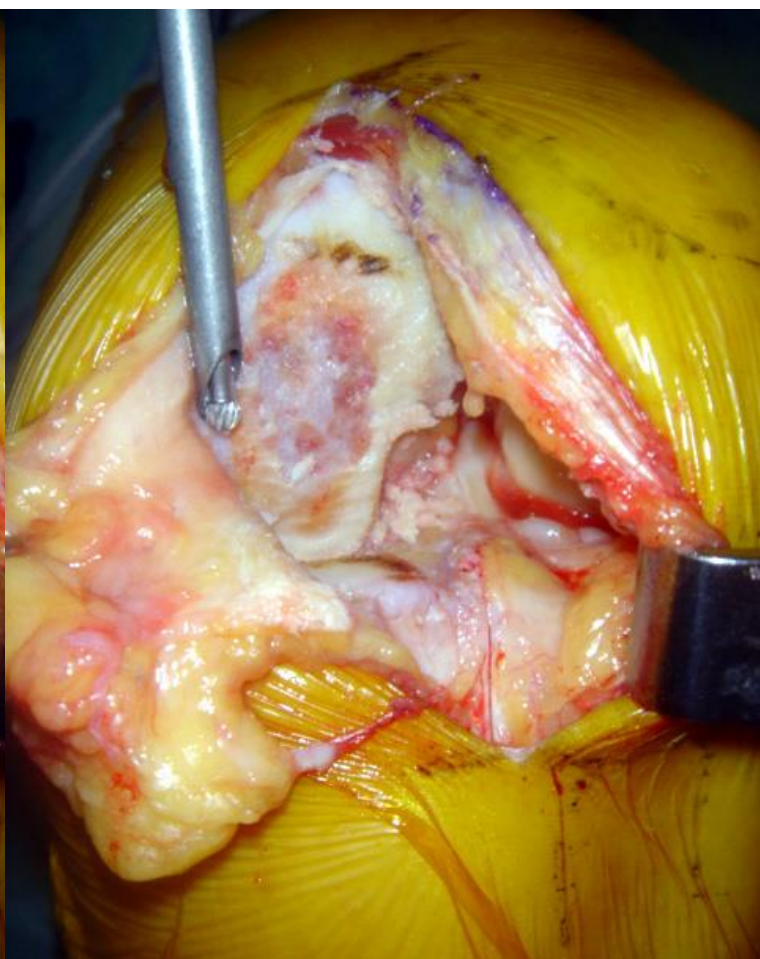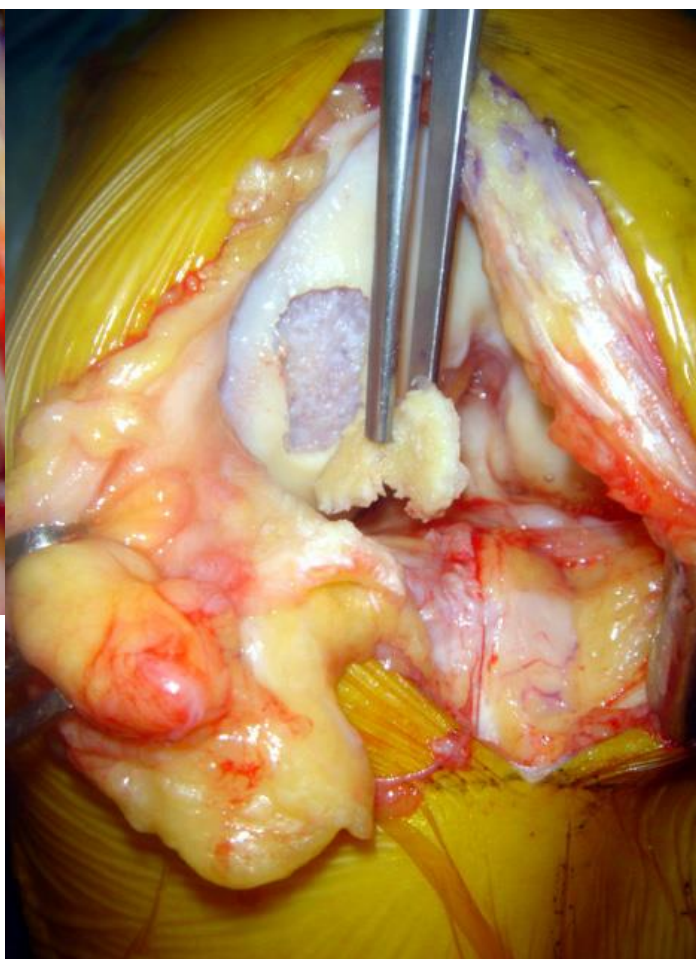
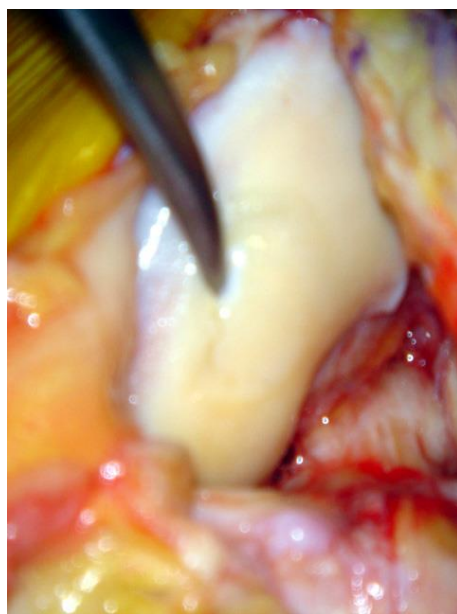


Lateral UNI Right Knee



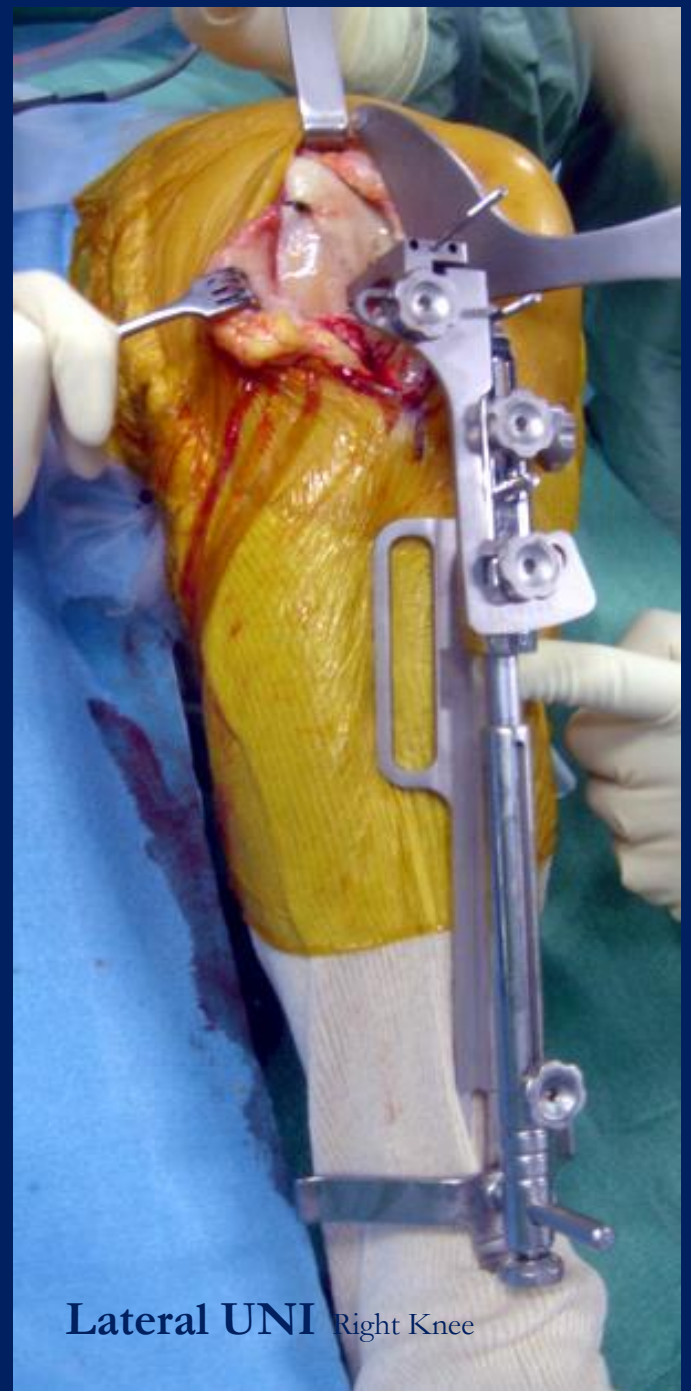
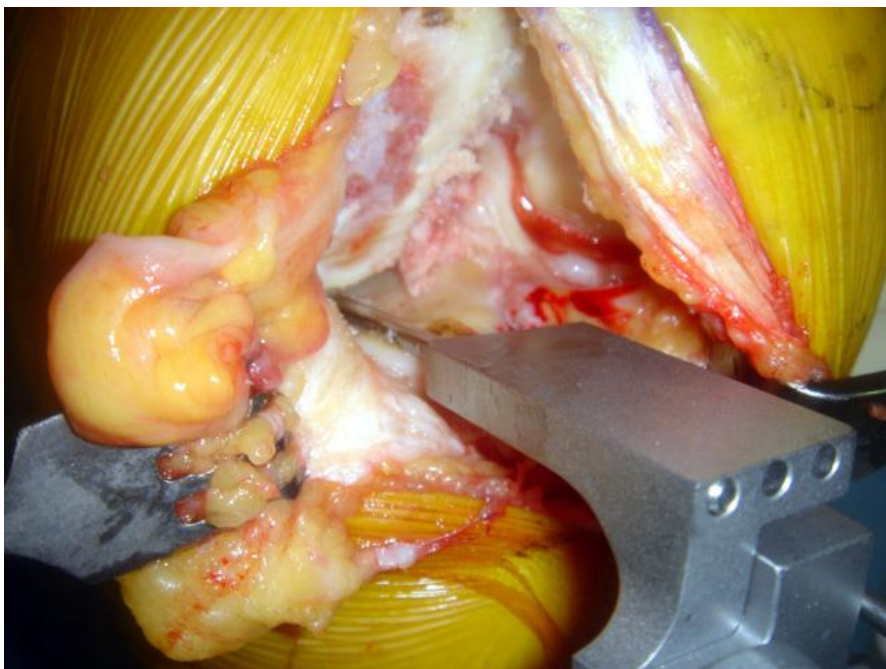
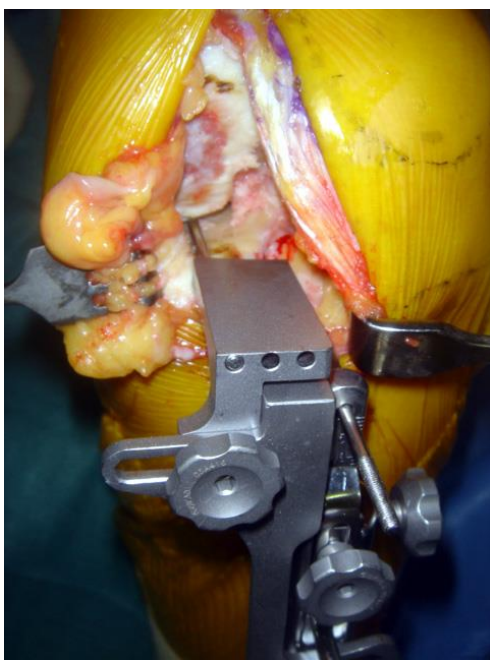
Medial UNI Left Knee



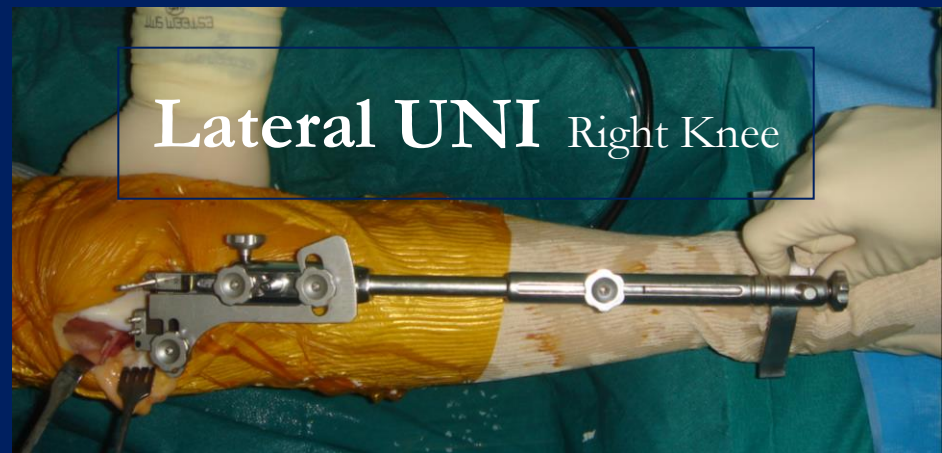
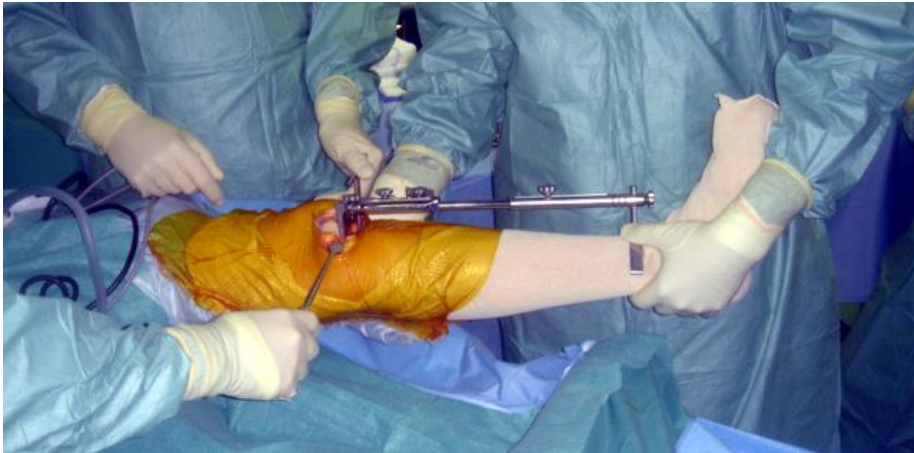
Surgical Technique

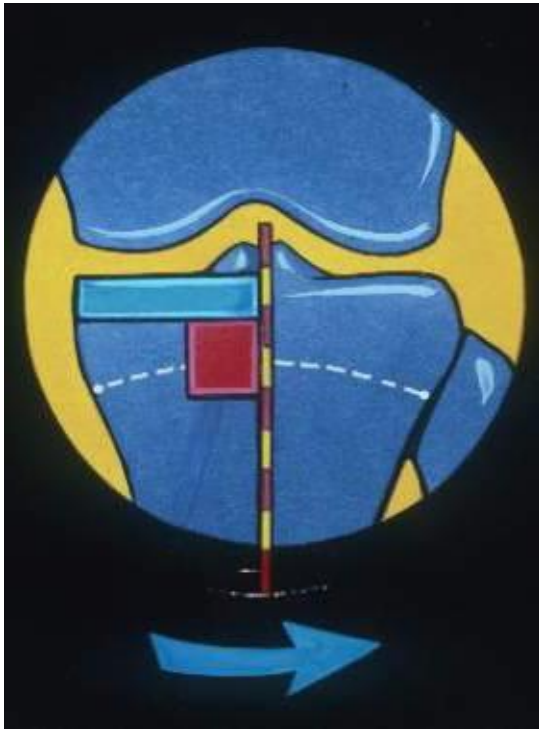
1. Approach
2. Tibial cut
3. Femoral cut
4. Trials
5. Fixation



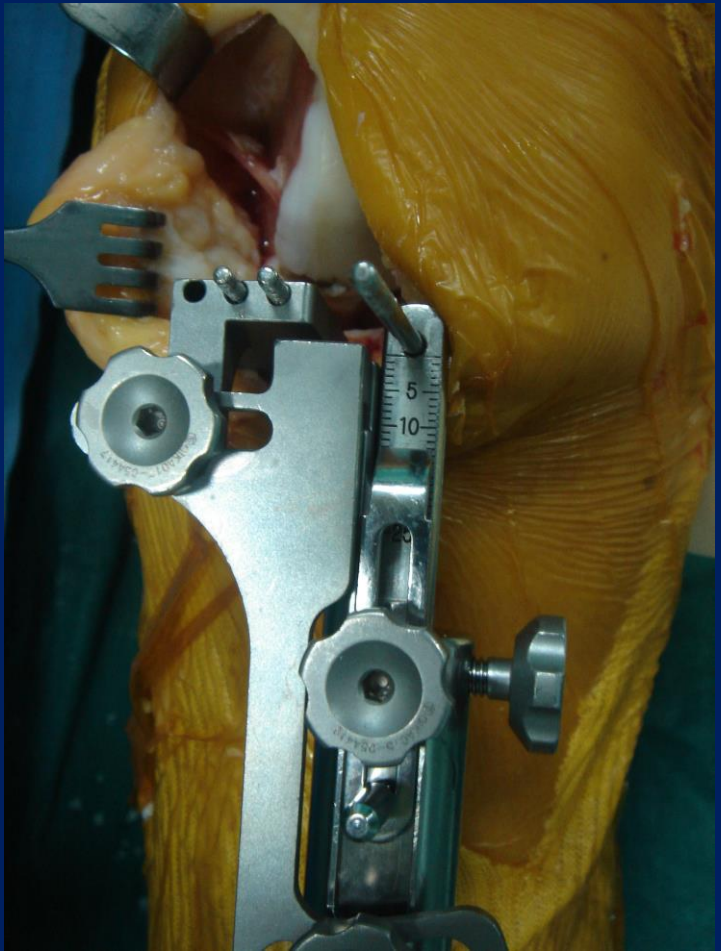
Lateral UNI Right Knee



Lateral UNI Right Knee



Medial UNI Right Knee

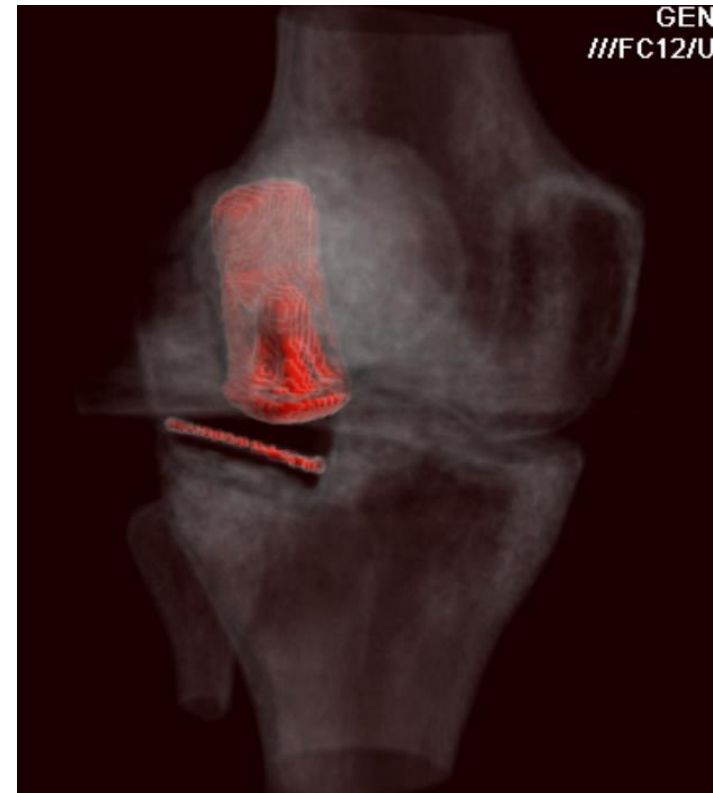

Positionnement tibial de l'UNI

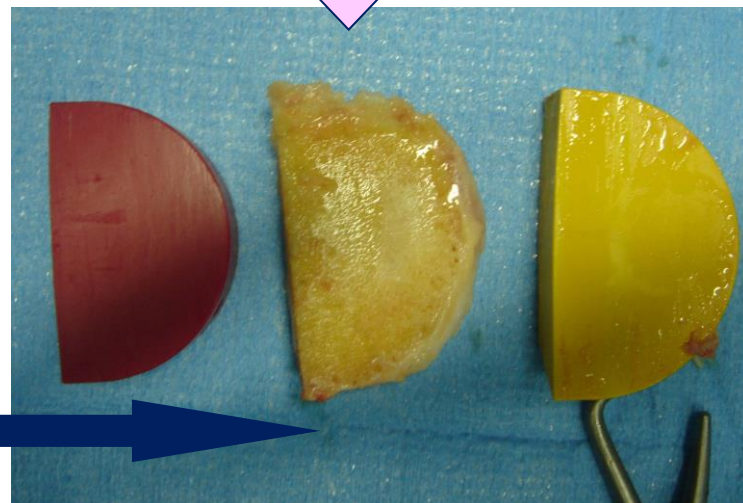
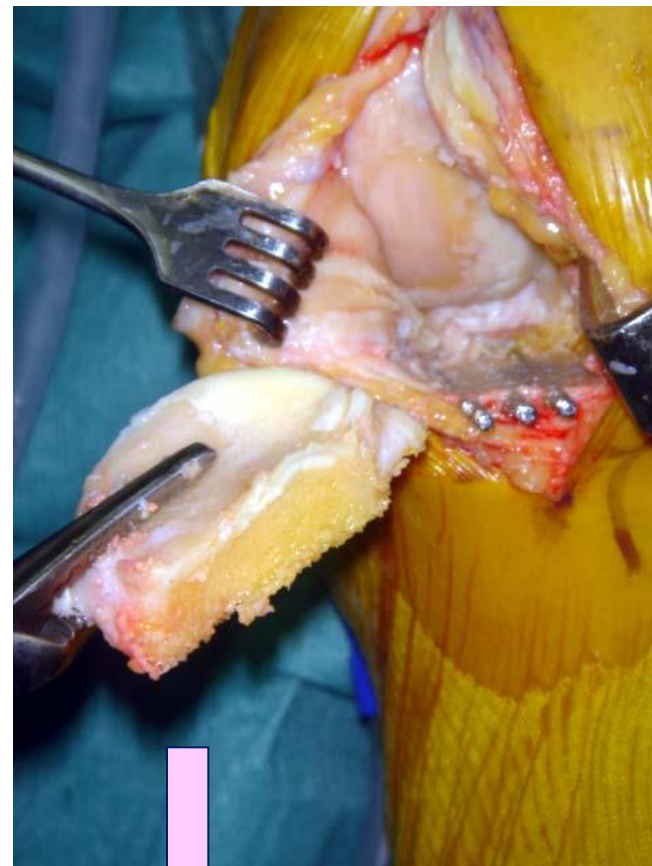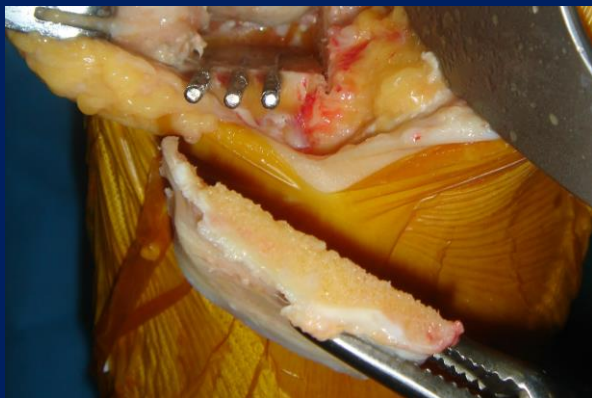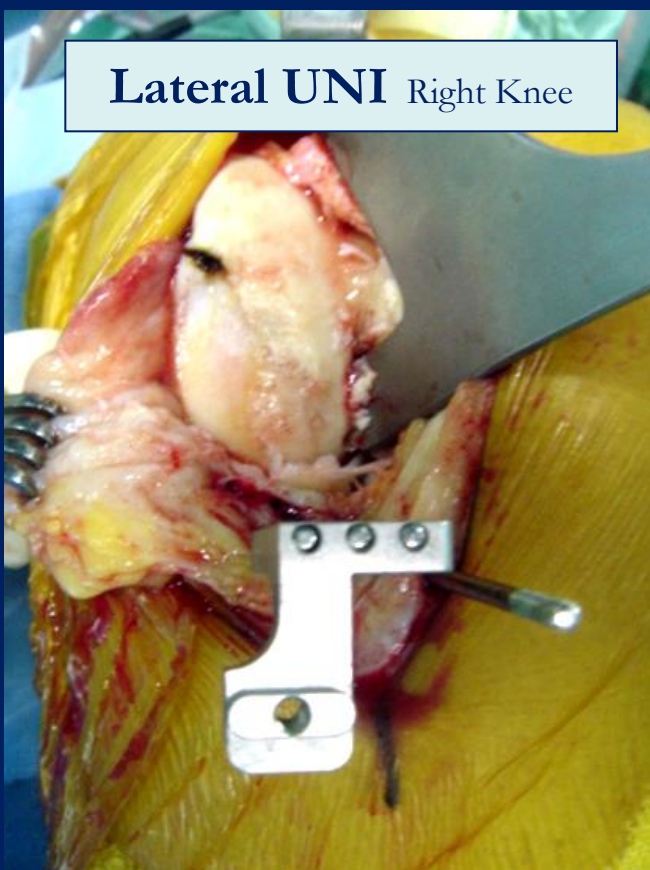
Inclinaison frontale (angle ψ)

- UNI interne \longrightarrow varus
 $\psi = 84,49^\circ$
- UNI externe \longrightarrow valgus
 $\psi = 91,27^\circ$

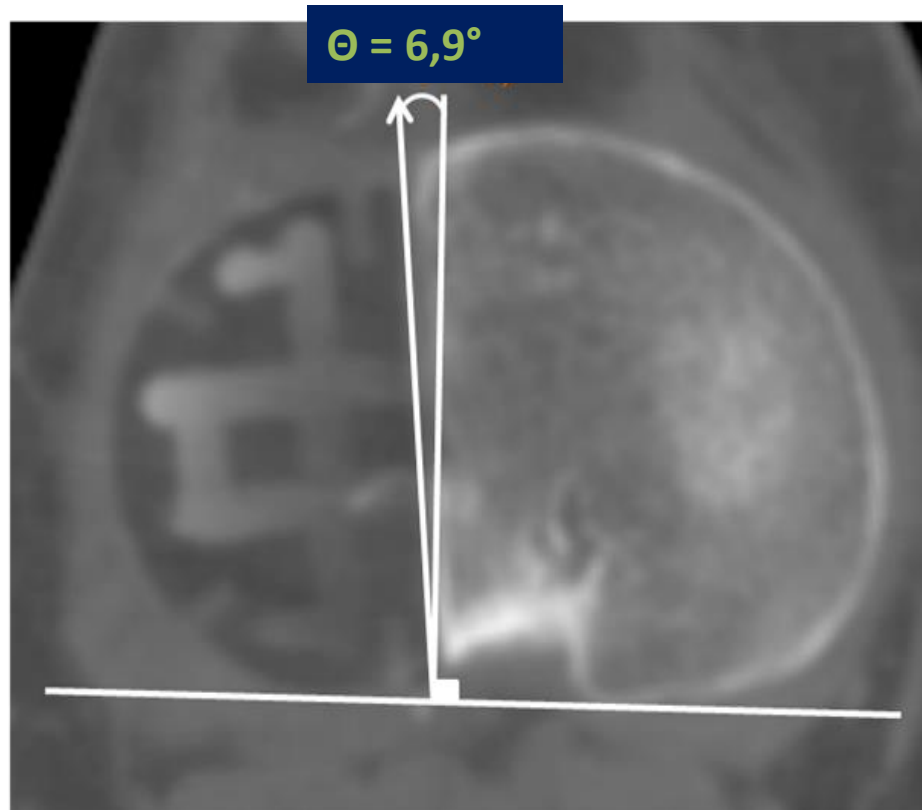
($P \leq 0,0000.$)



Lateral UNI Right Knee

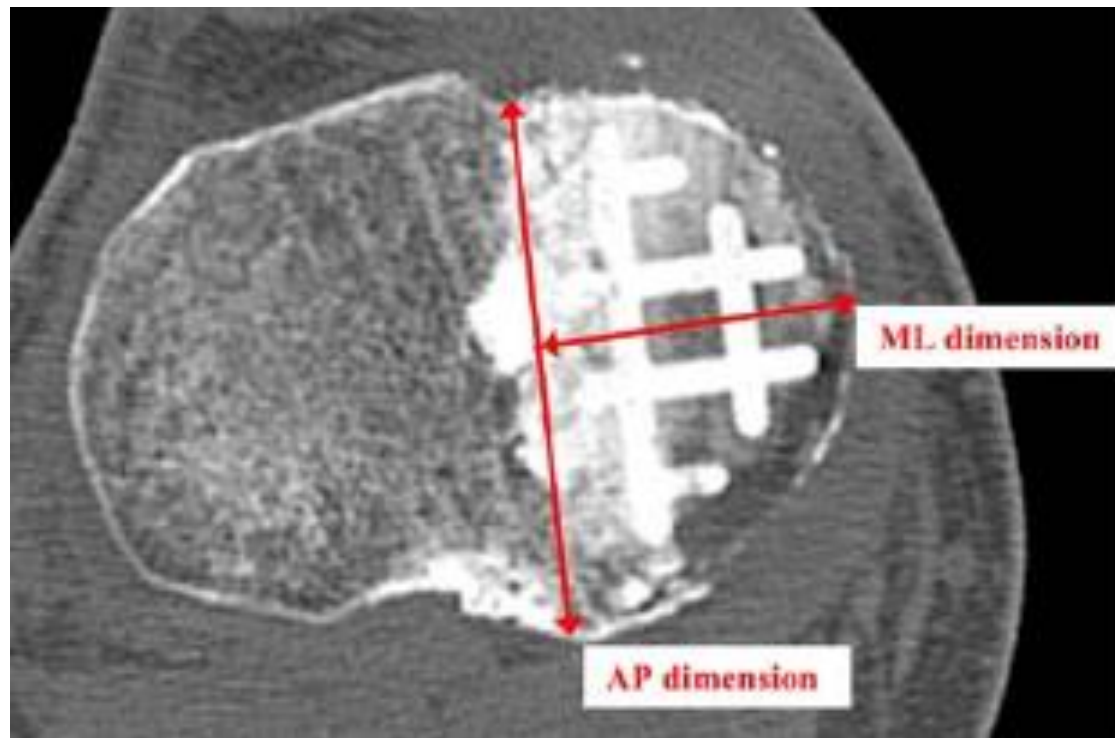


Positionnement tibial de l'UNI en Rotation tibiale ?



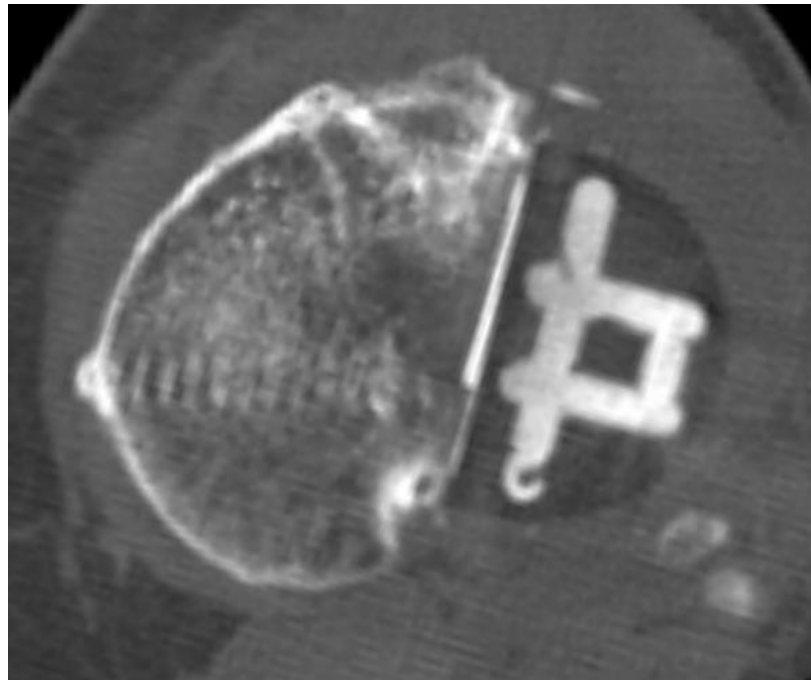
NS (p=0,717)

plateau tibial

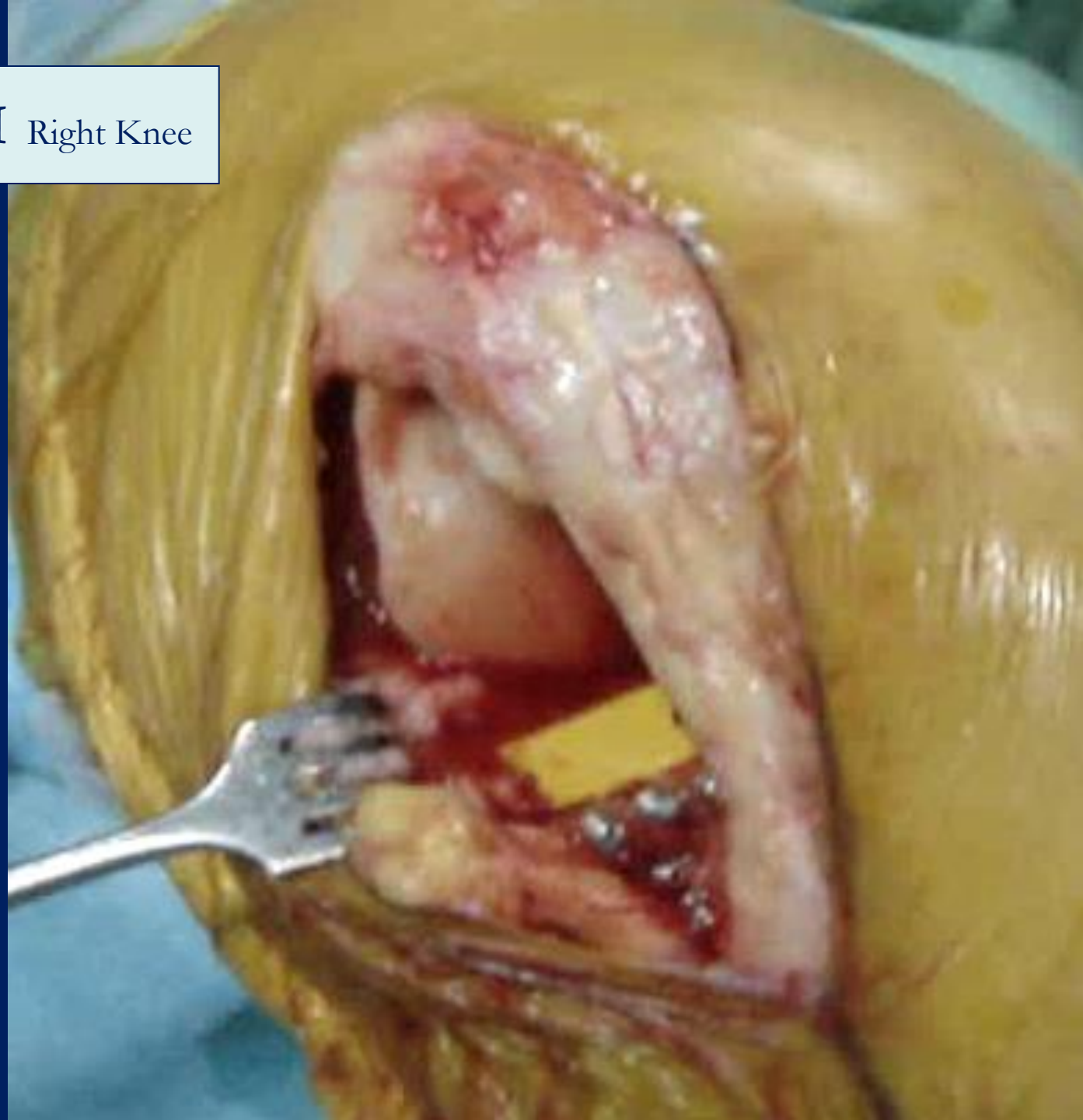

Positionnement de l'UNI la rotation tibiale ?

- Mauvais positionnement ?

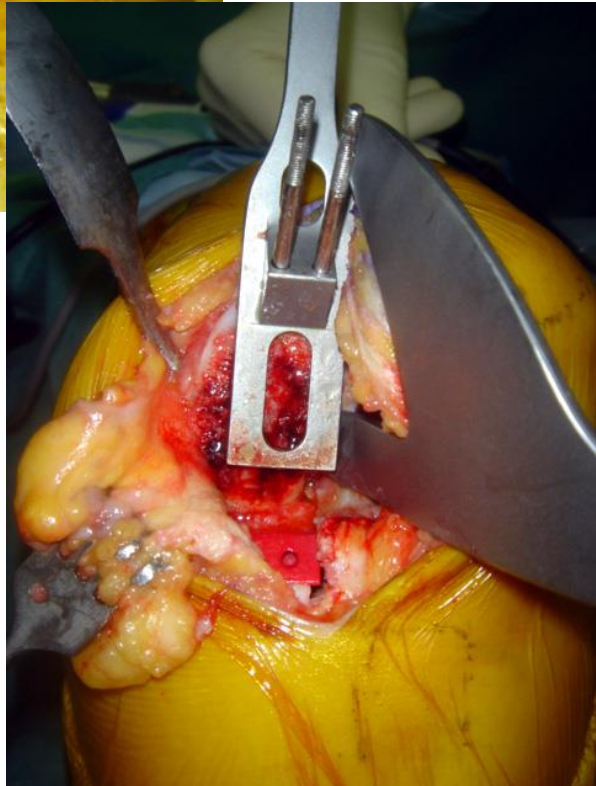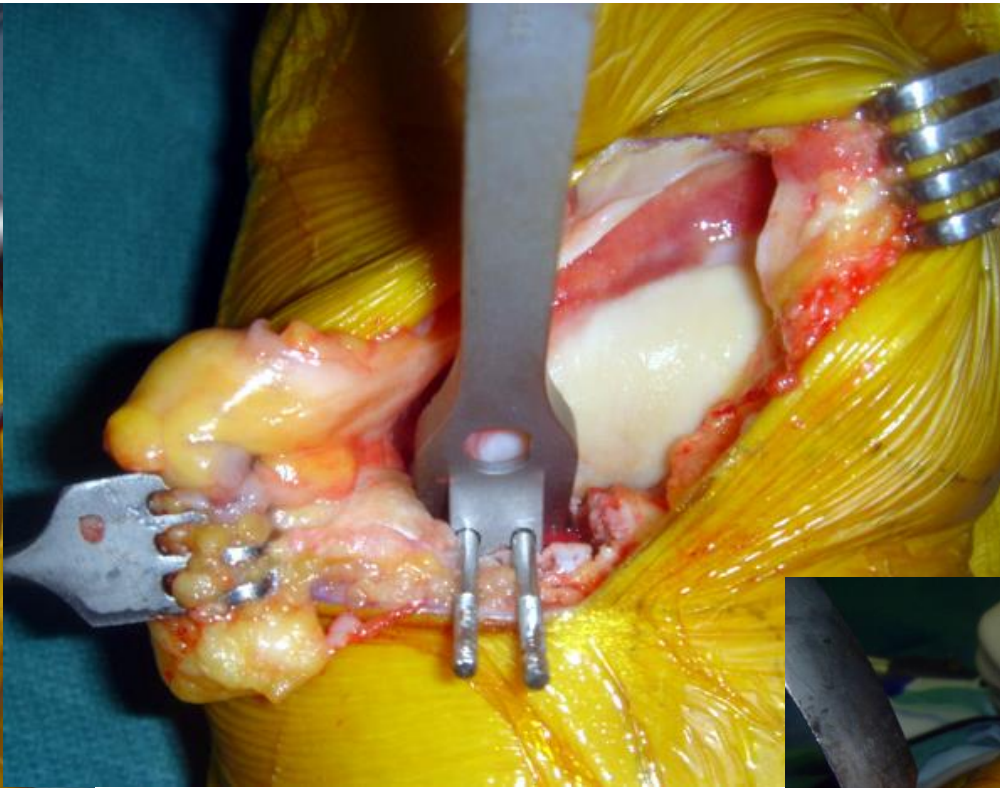
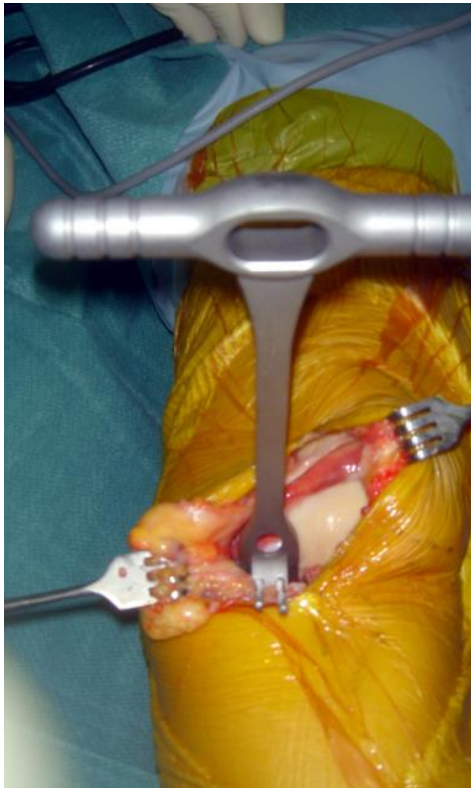


Lateral UNI Right Knee

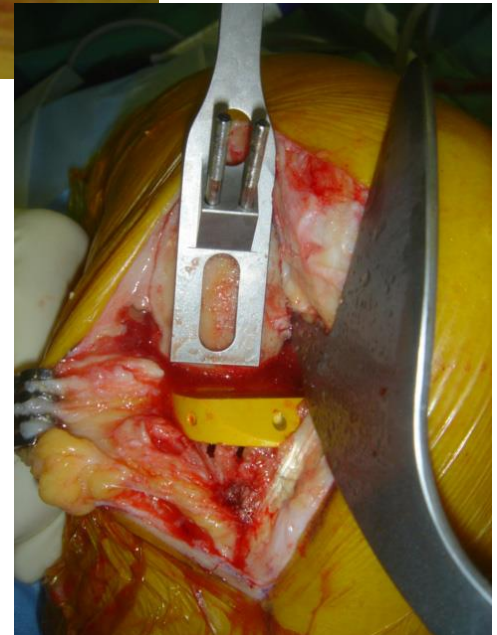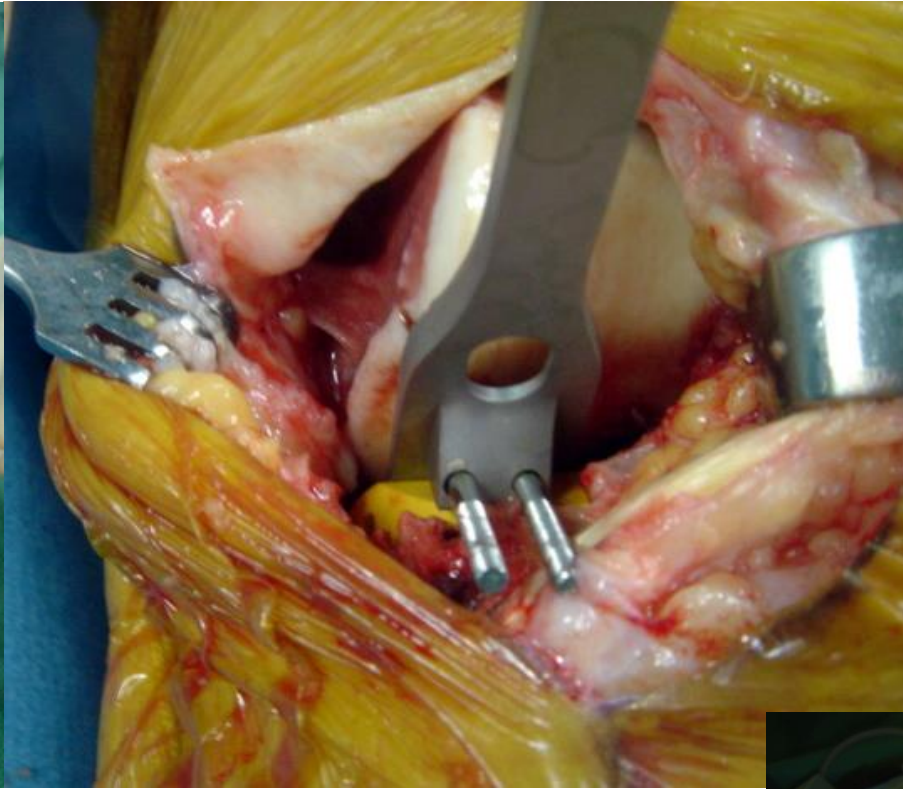

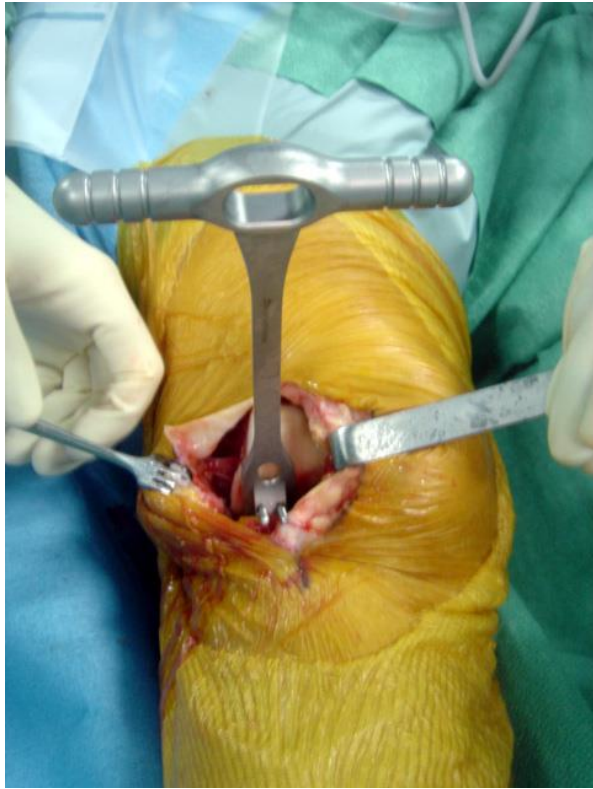
Surgical Technique

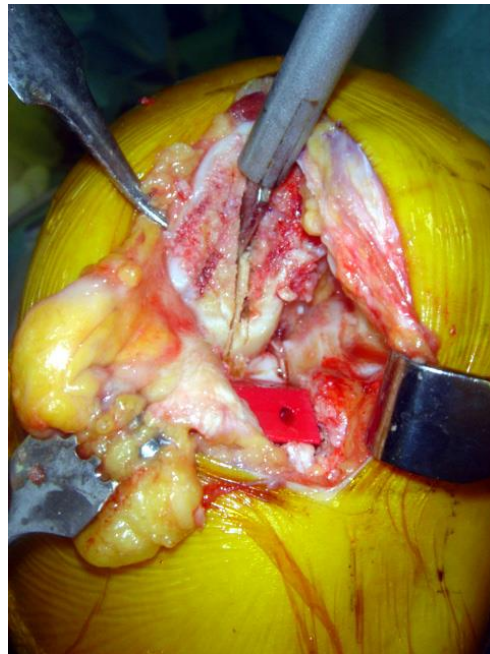
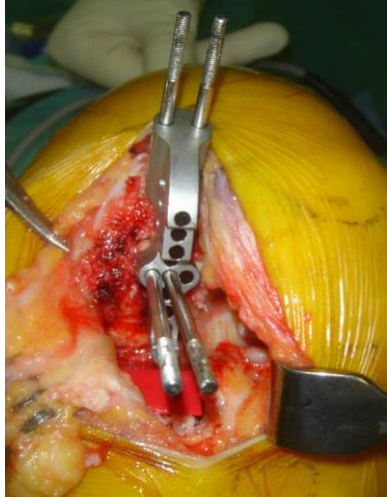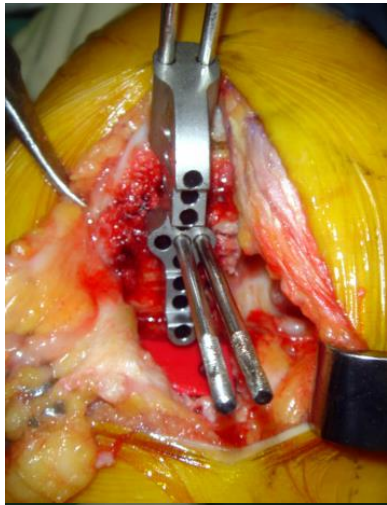
1. Approach
2. Tibial cut
3. Femoral cut
4. Trials
5. Fixation



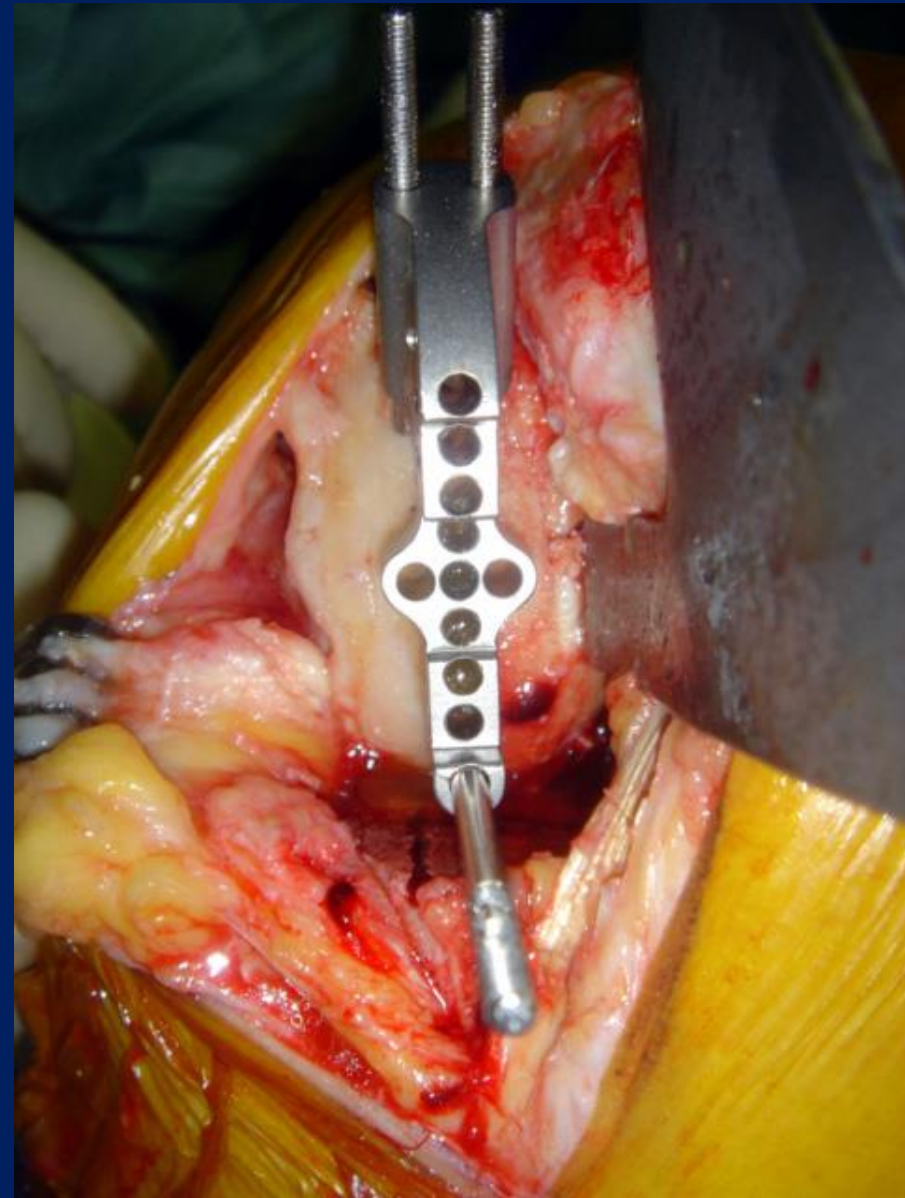
Medial UNI Left Knee



Lateral UNI Right Knee



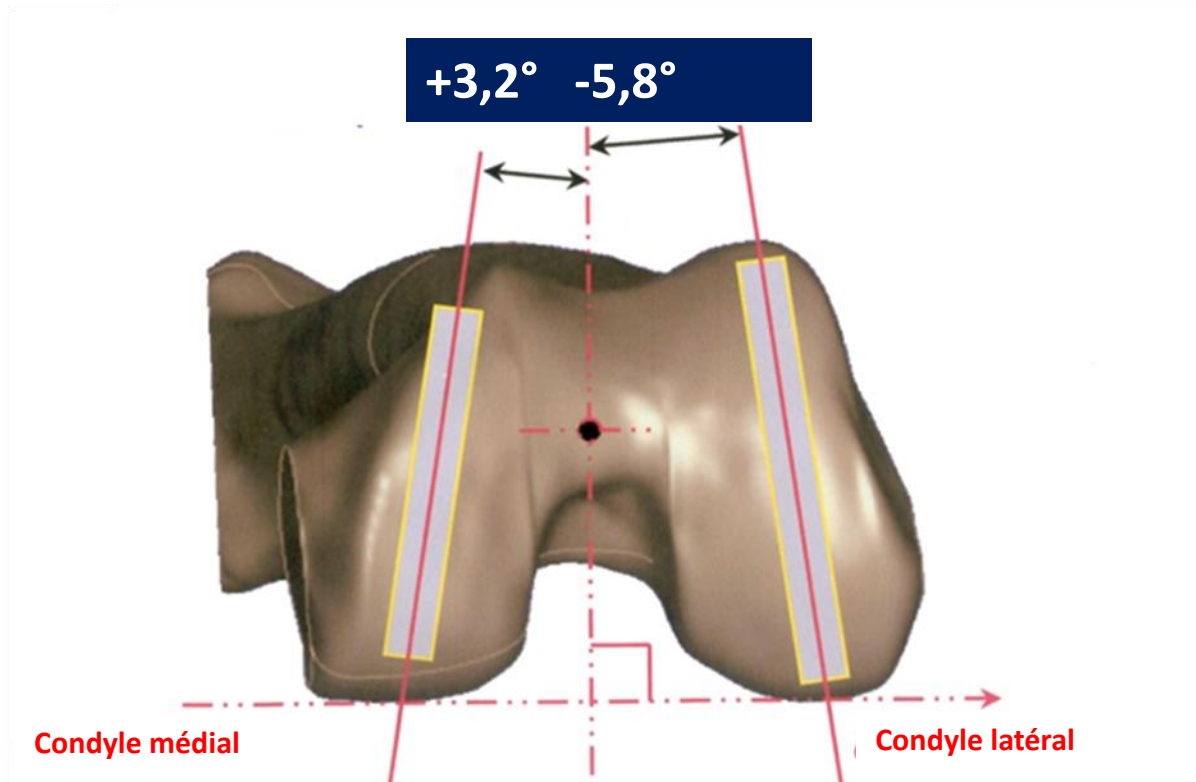
Medial UNI Left Knee



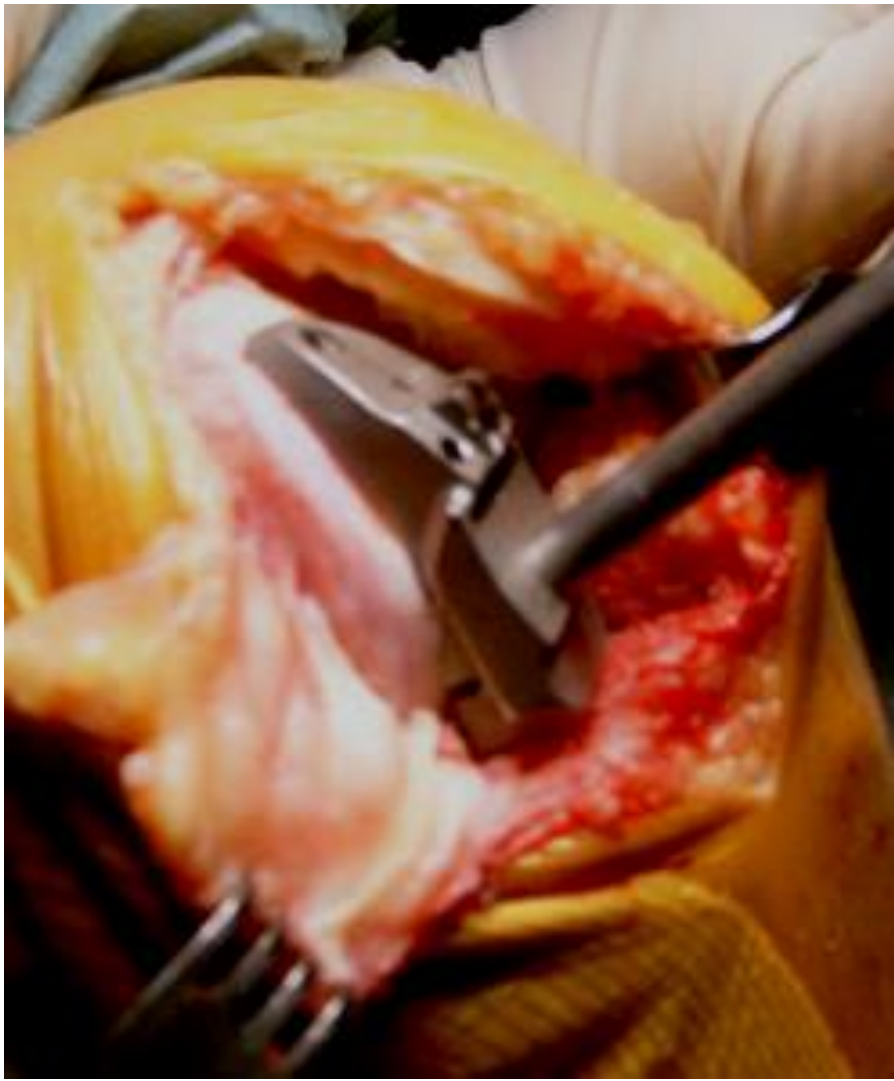
Lateral UNI Right Knee

Positionnement de l'UNI

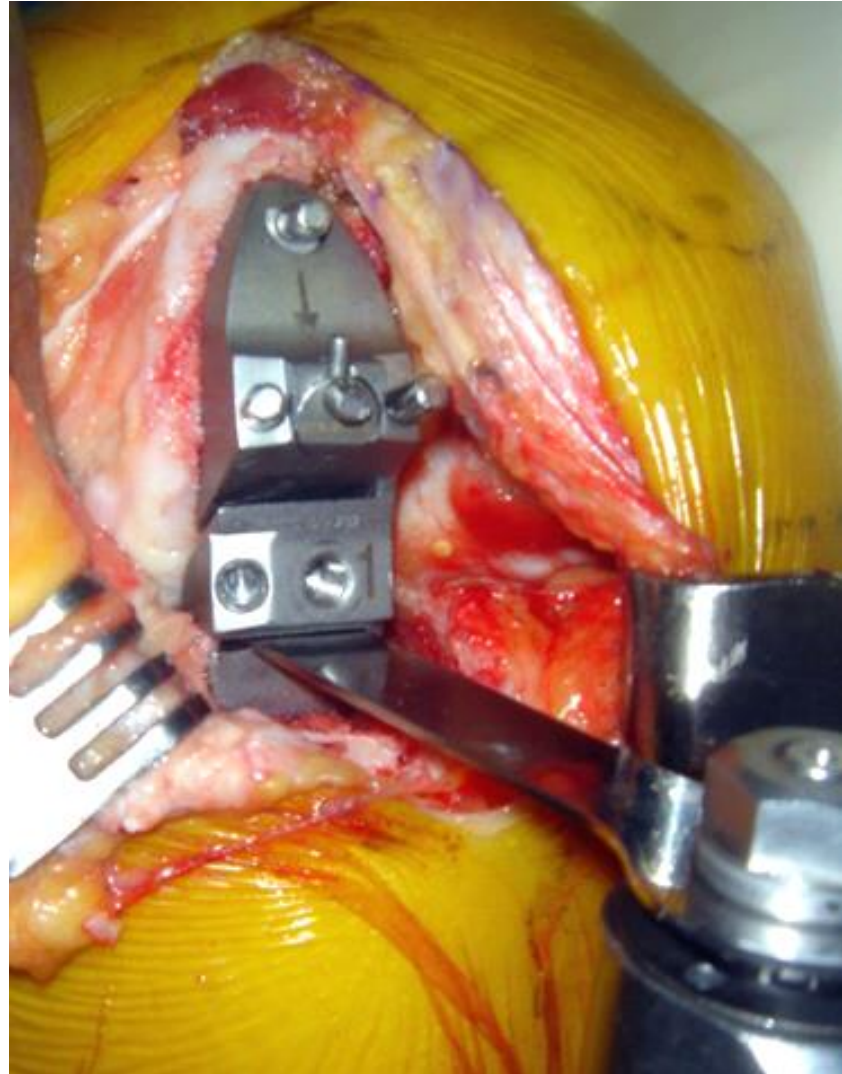
rotation de l'implant fémoral (angle β)

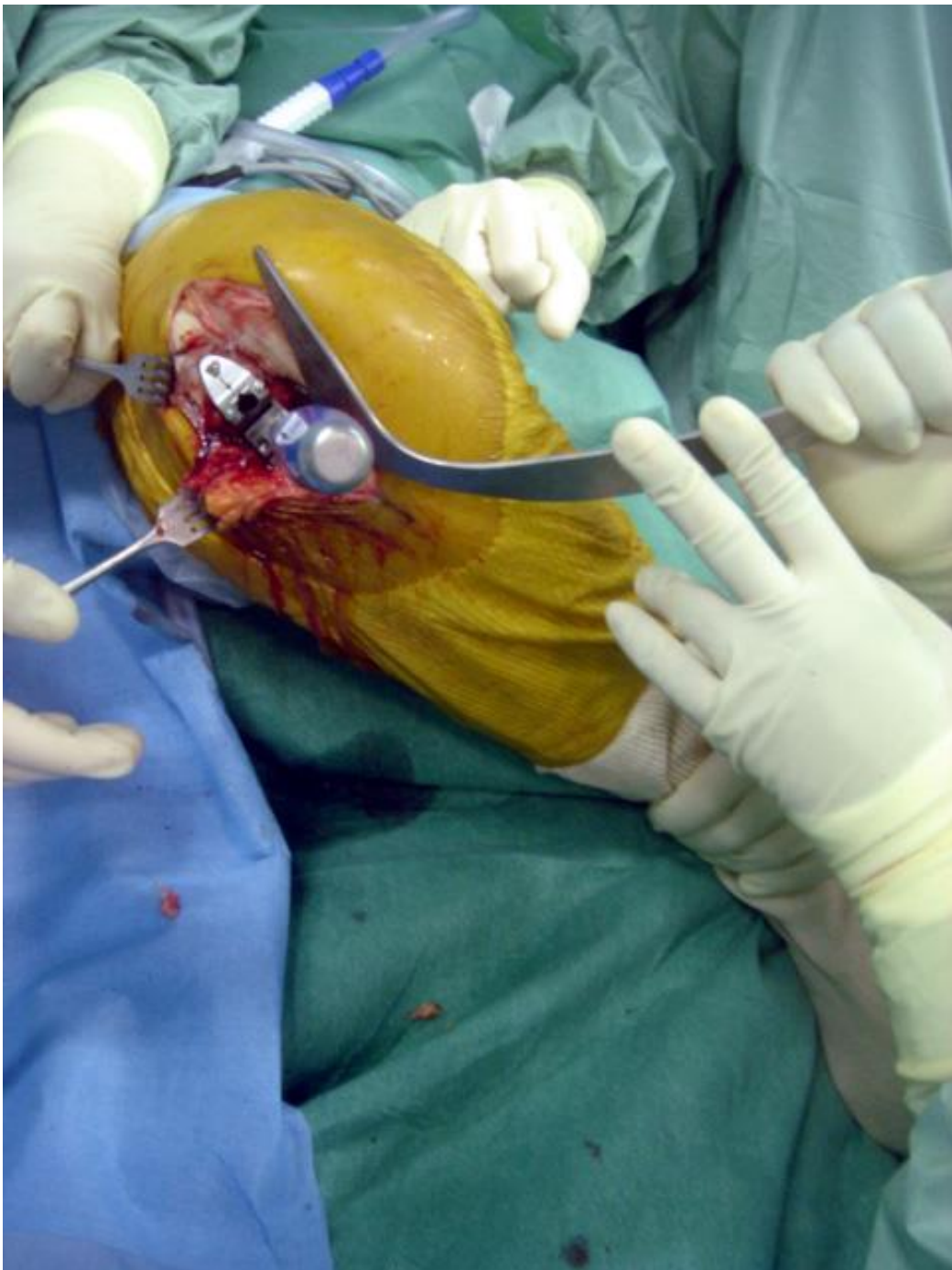

angle β médial / angle β latéral
P=0,00003

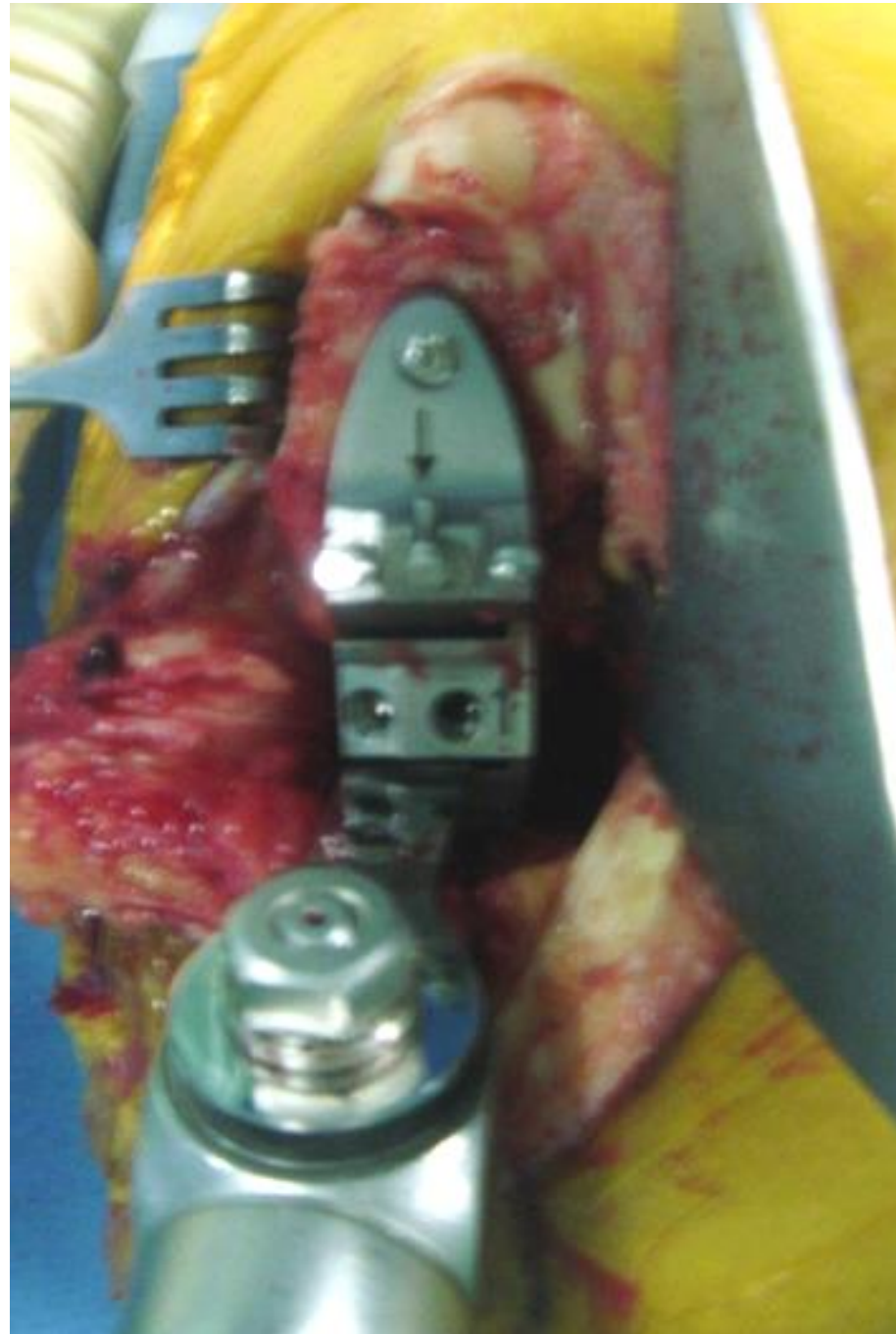
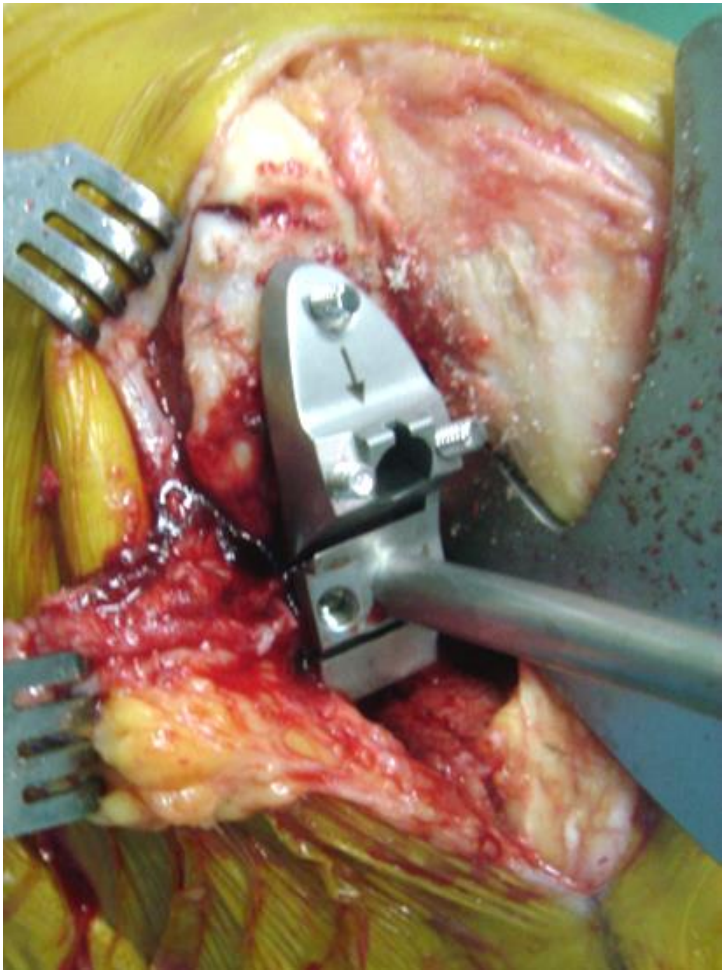


Medial UNI Left Knee





Lateral UNI Right Knee

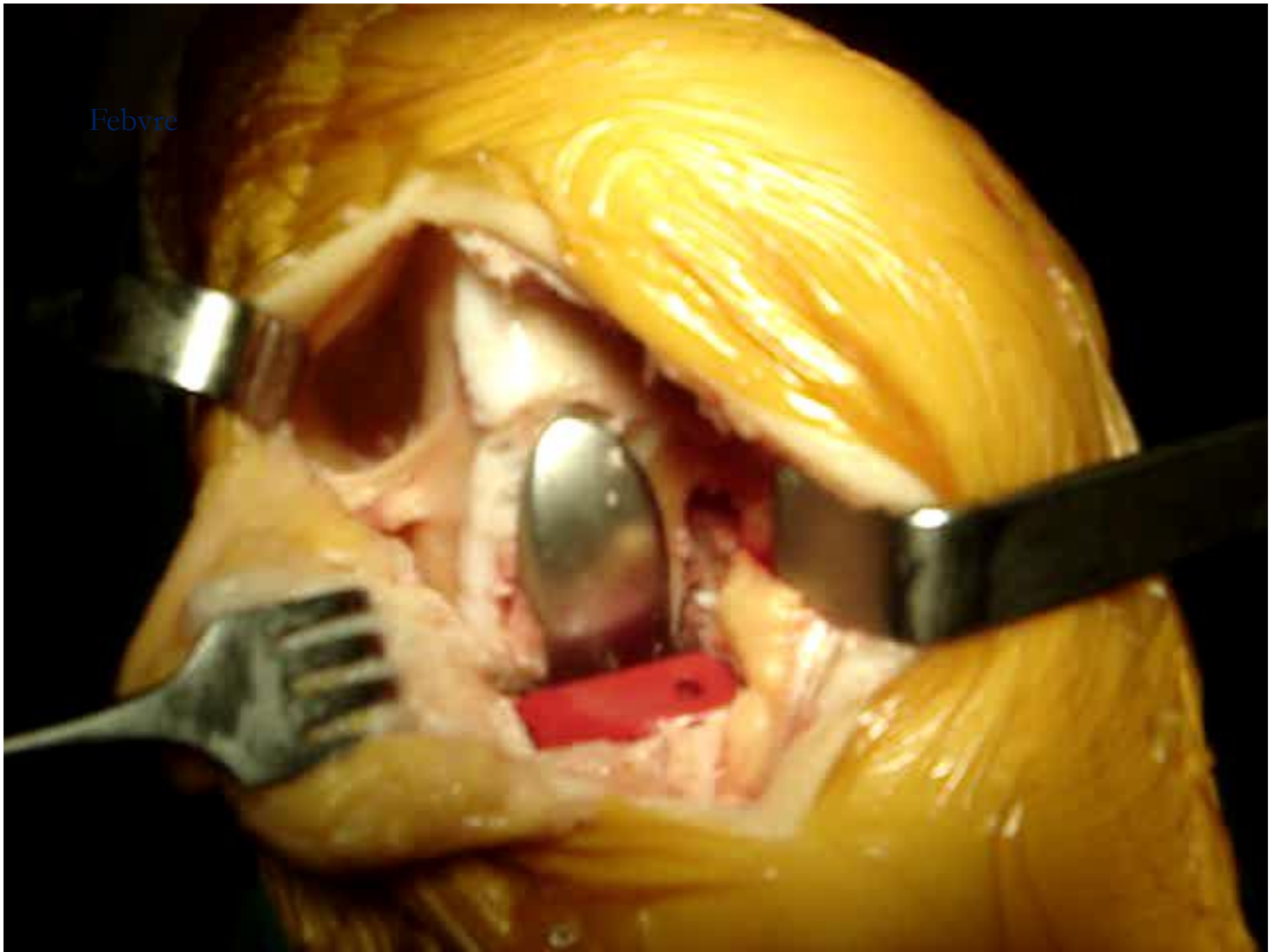


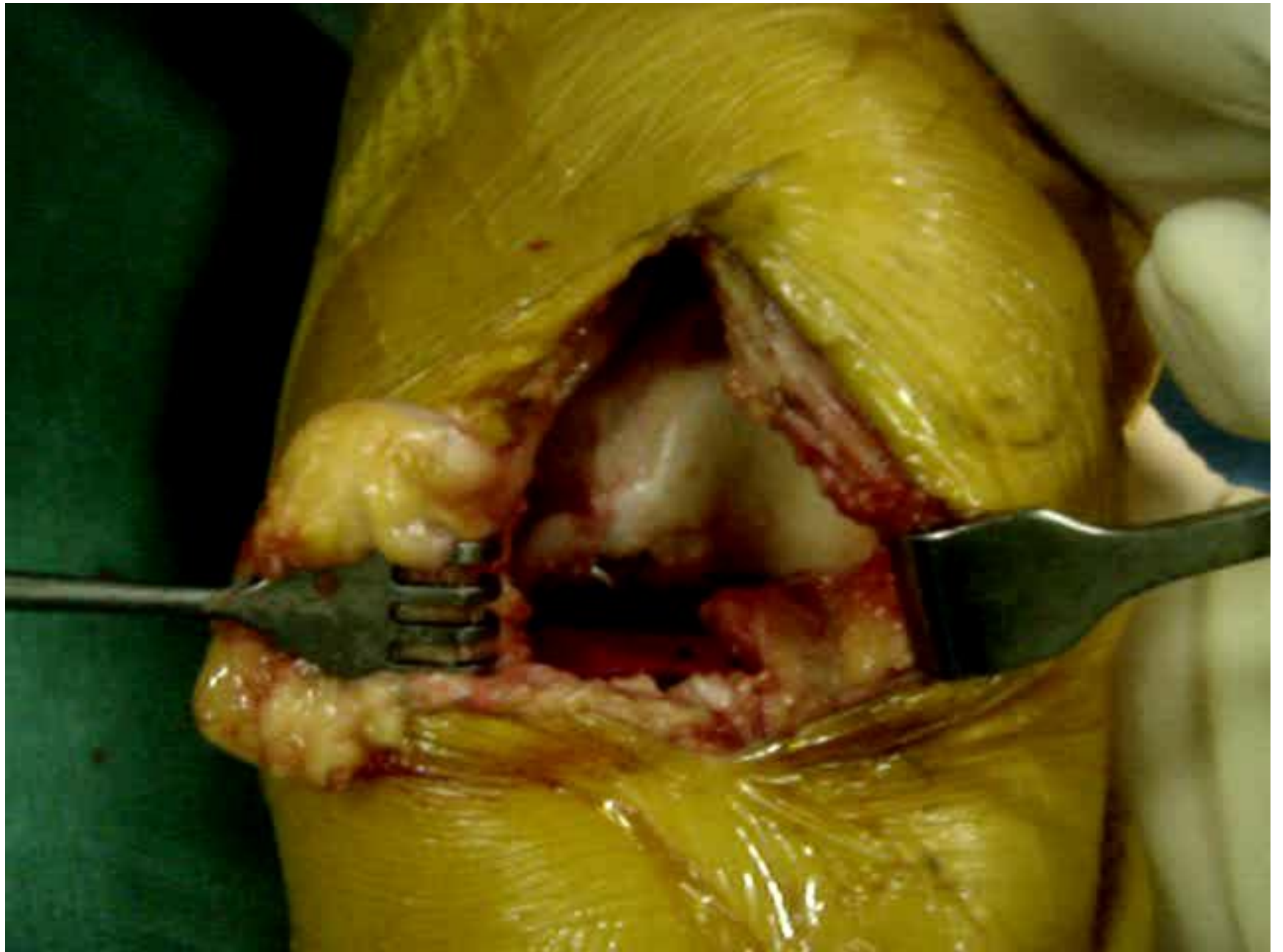
Lateral UNI Right Knee

Surgical Technique

1. Approach
2. Tibial cut
3. Femoral cut
4. Trials
5. Fixation

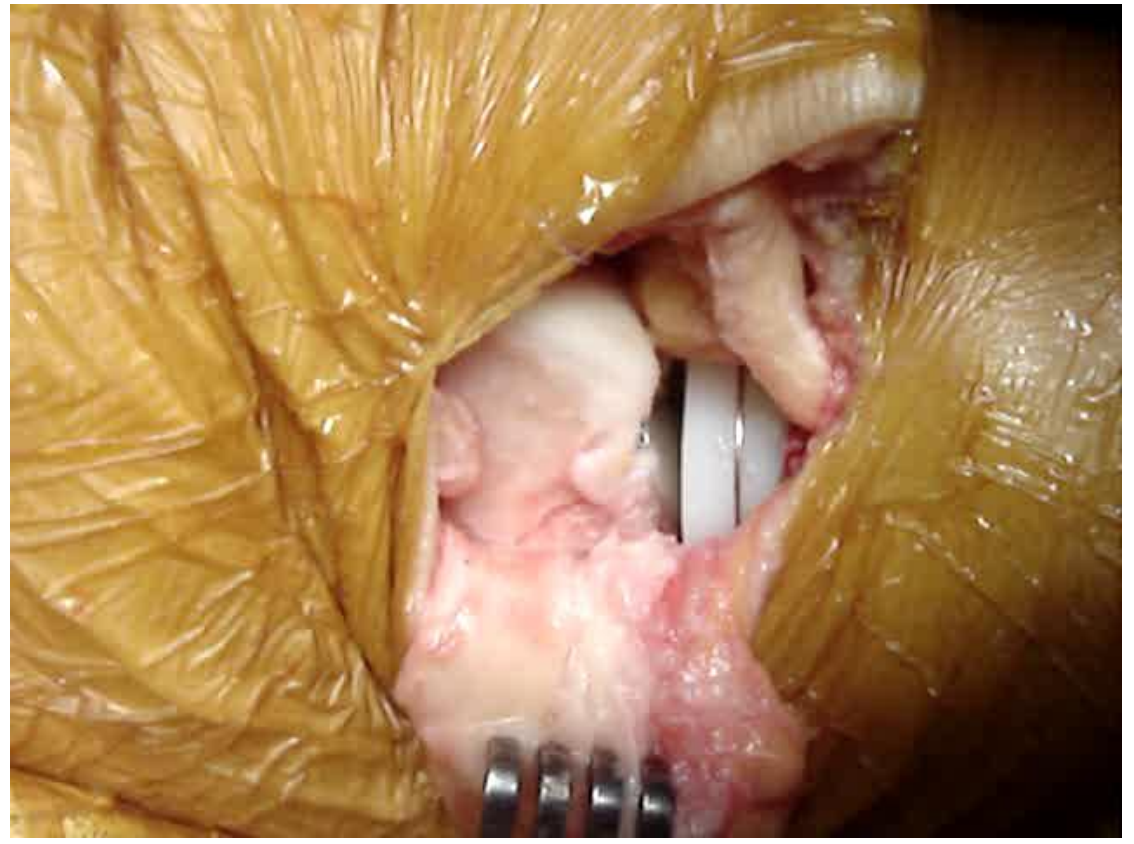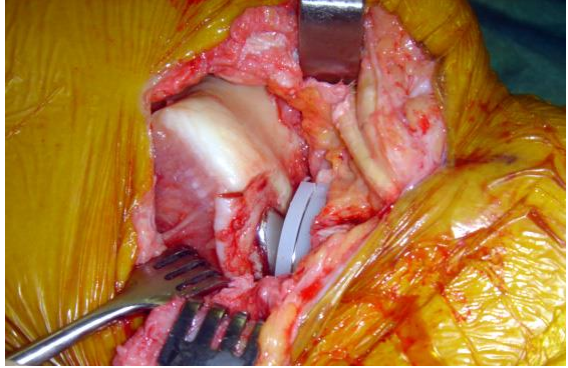
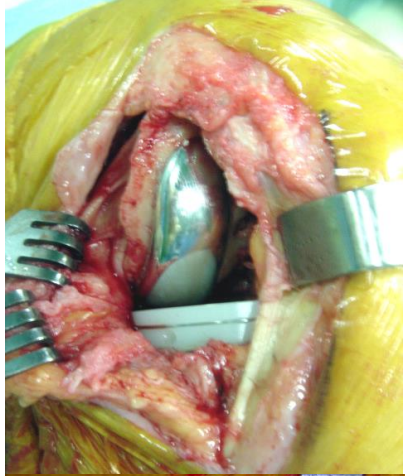
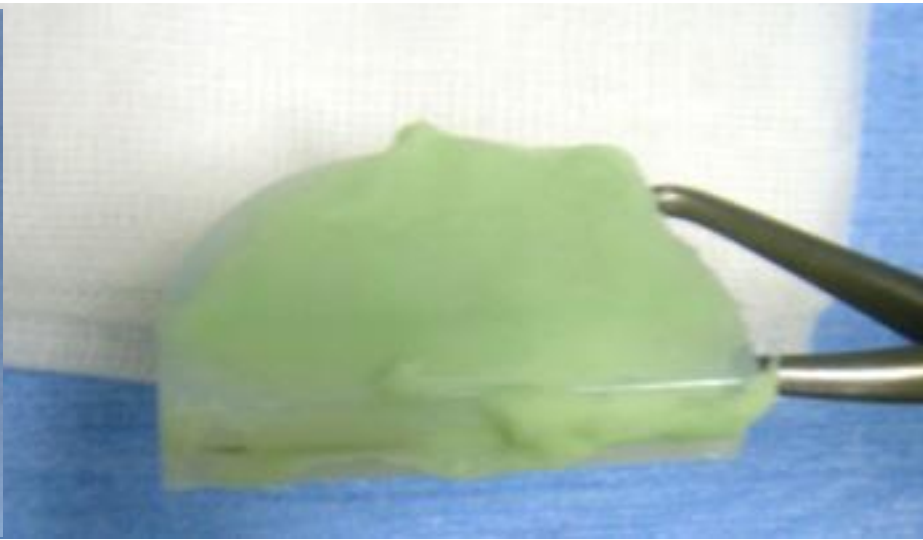
Febvre

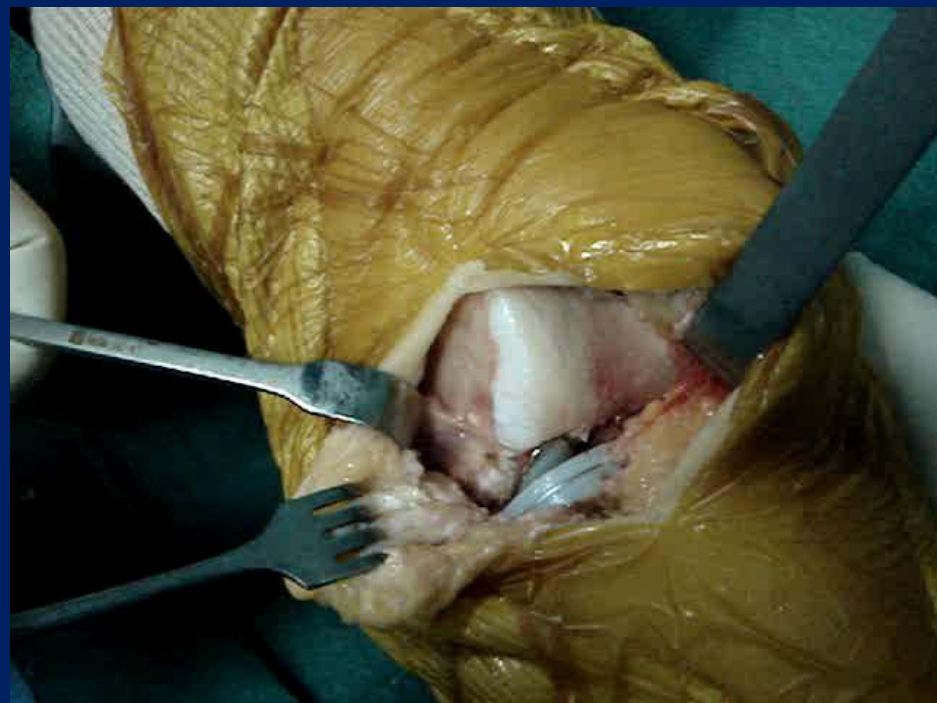
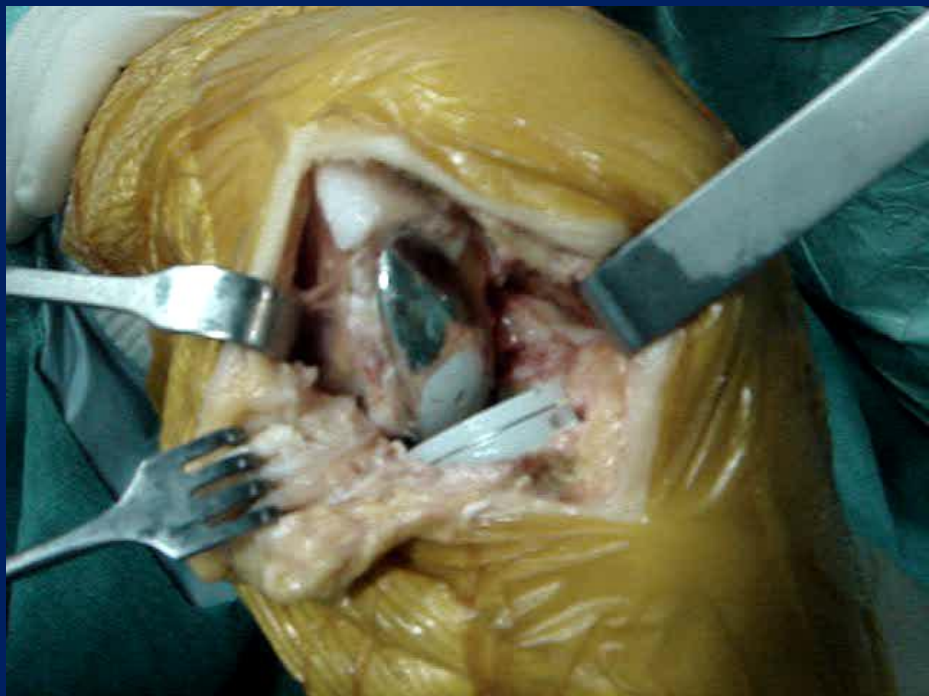
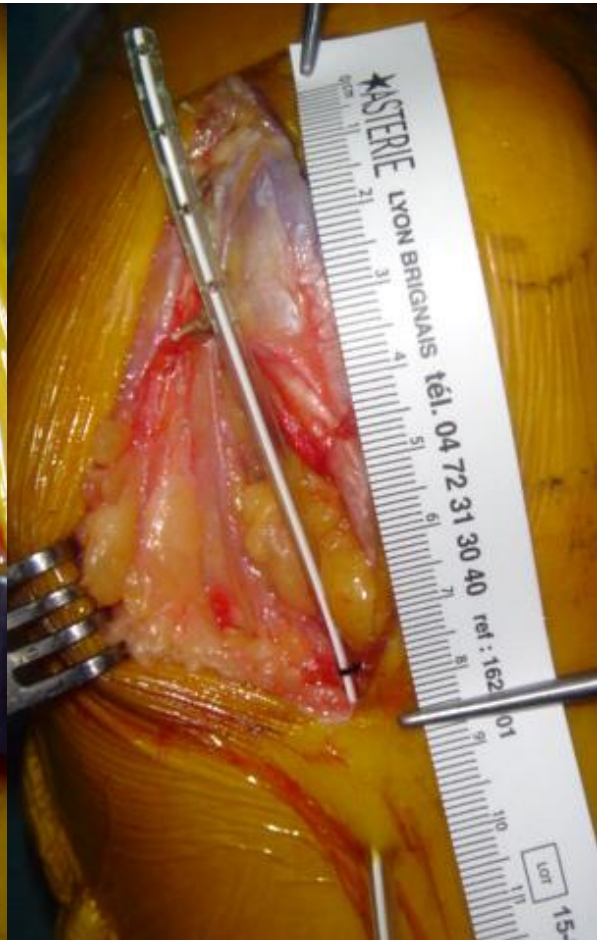
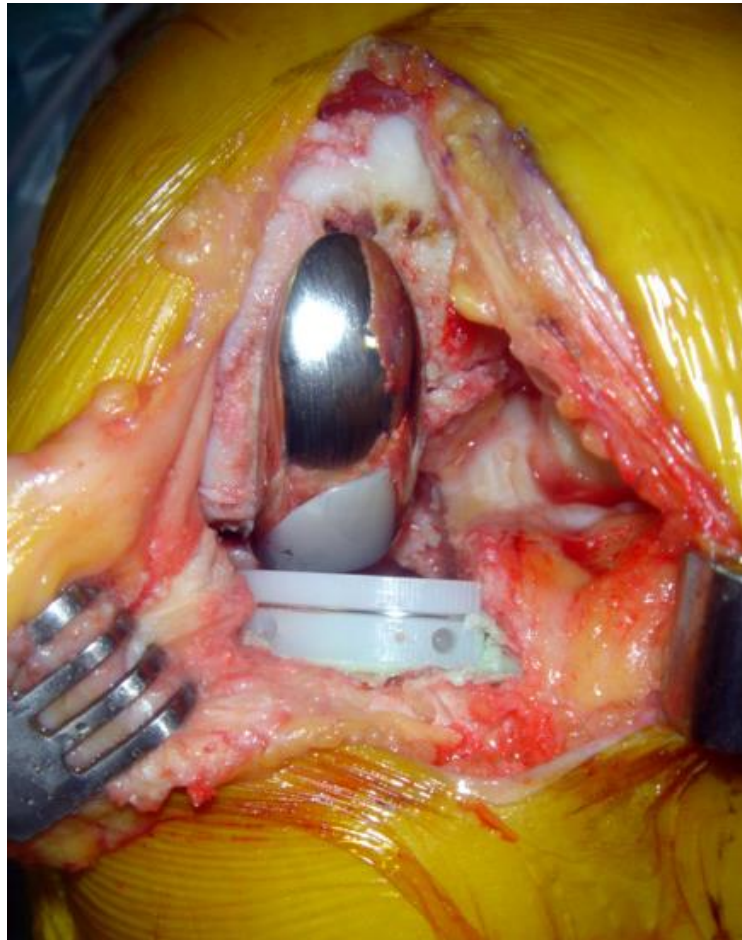
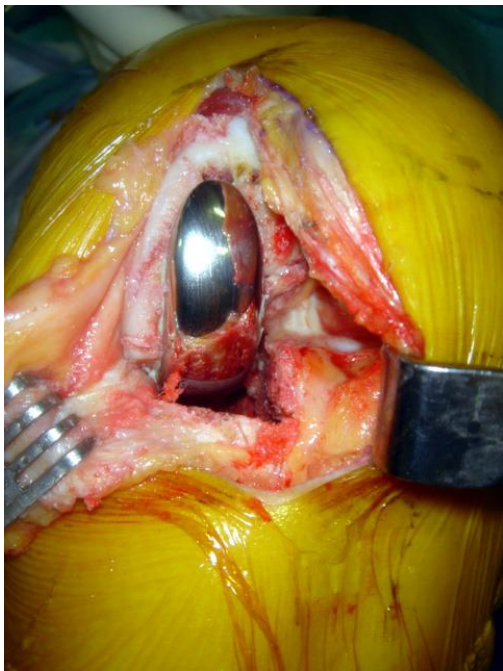


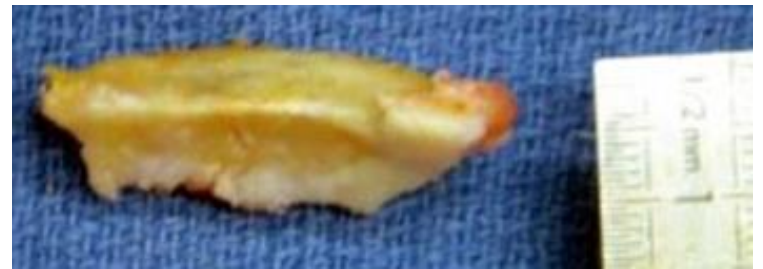
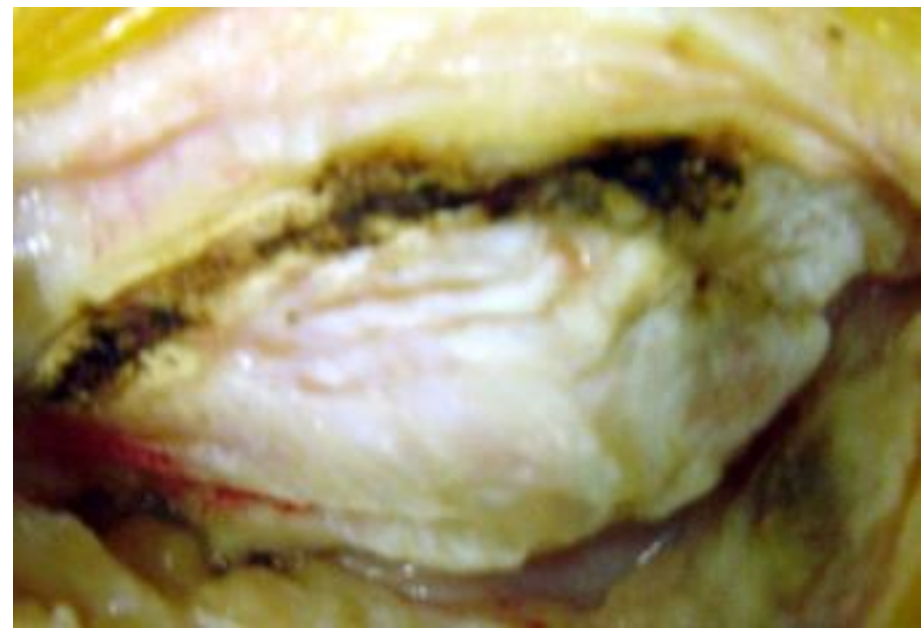
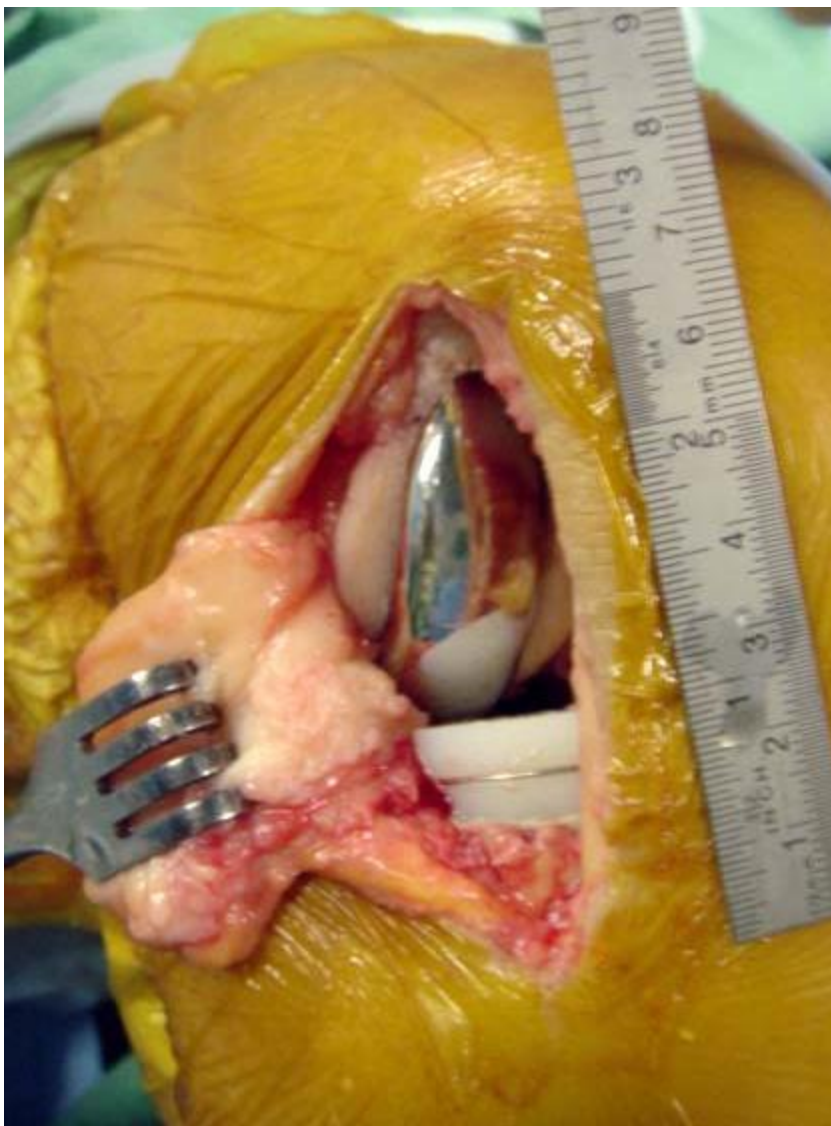Surgical Technique

1. Approach
2. Tibial cut
3. Femoral cut
4. Trials
5. Fixation



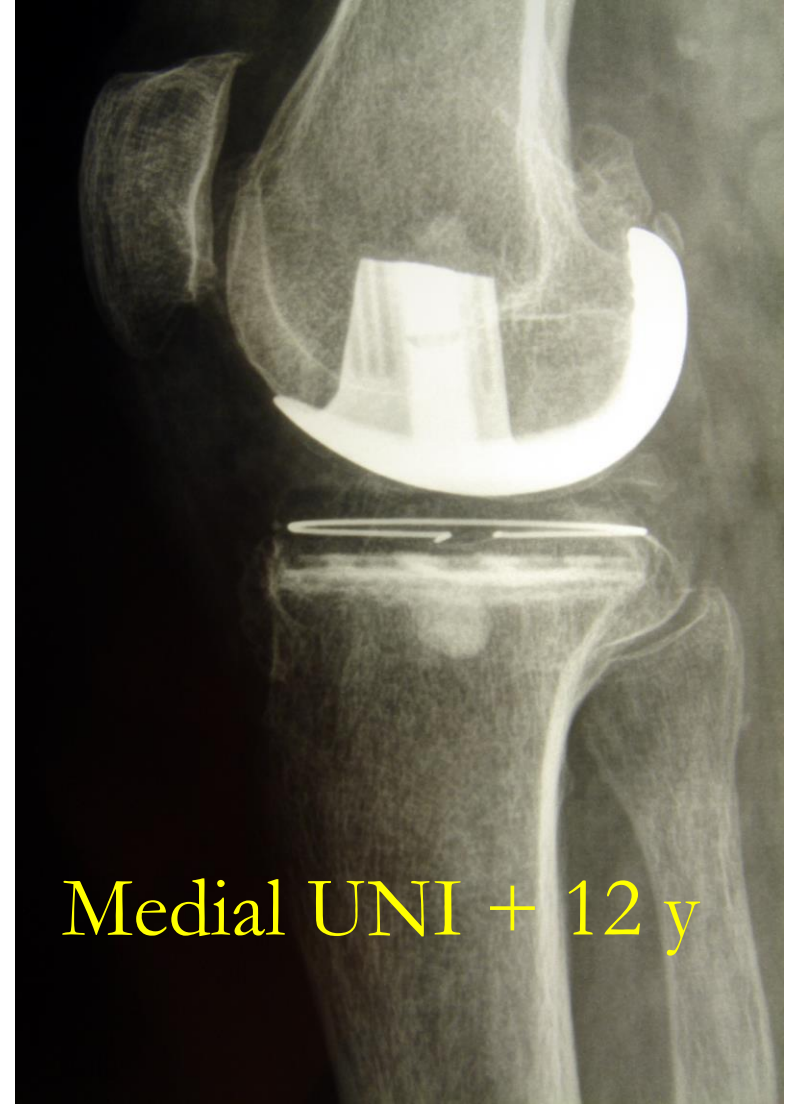
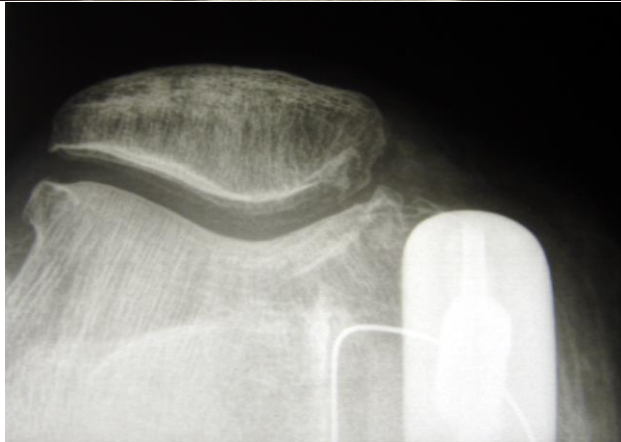
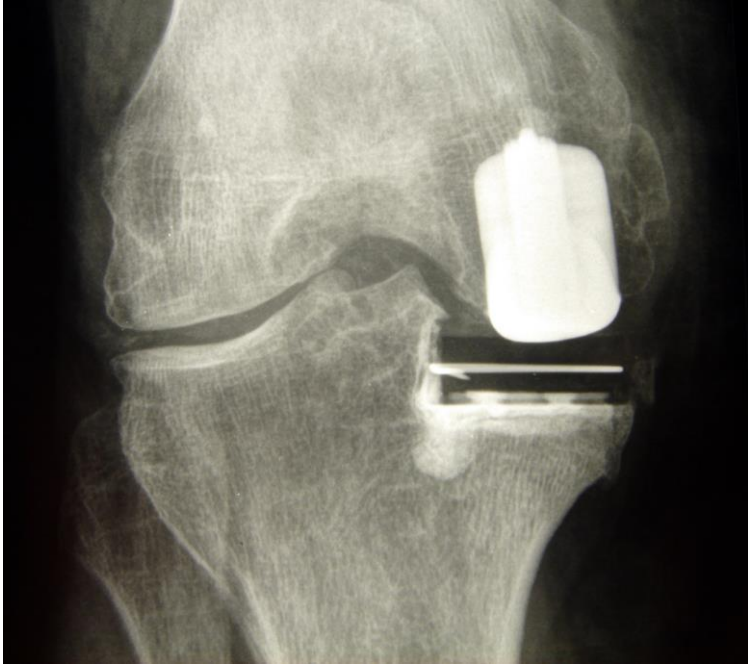




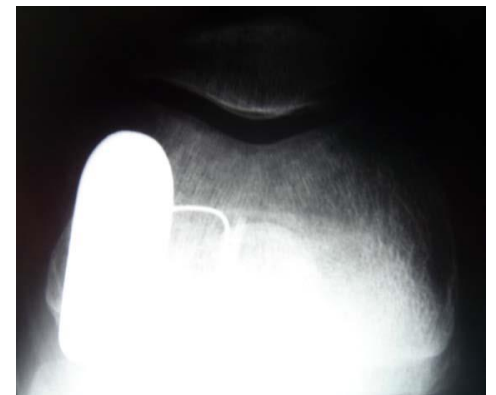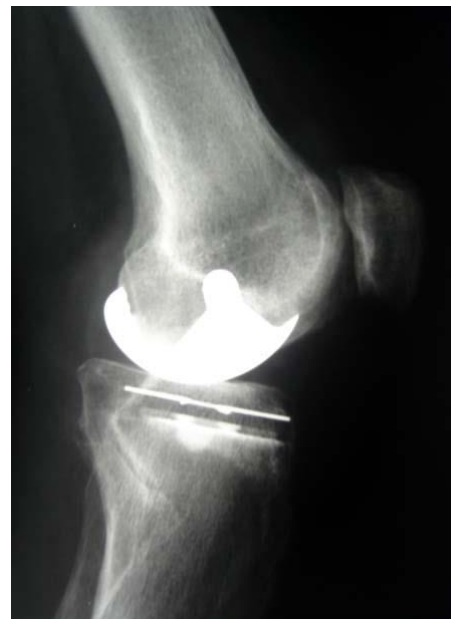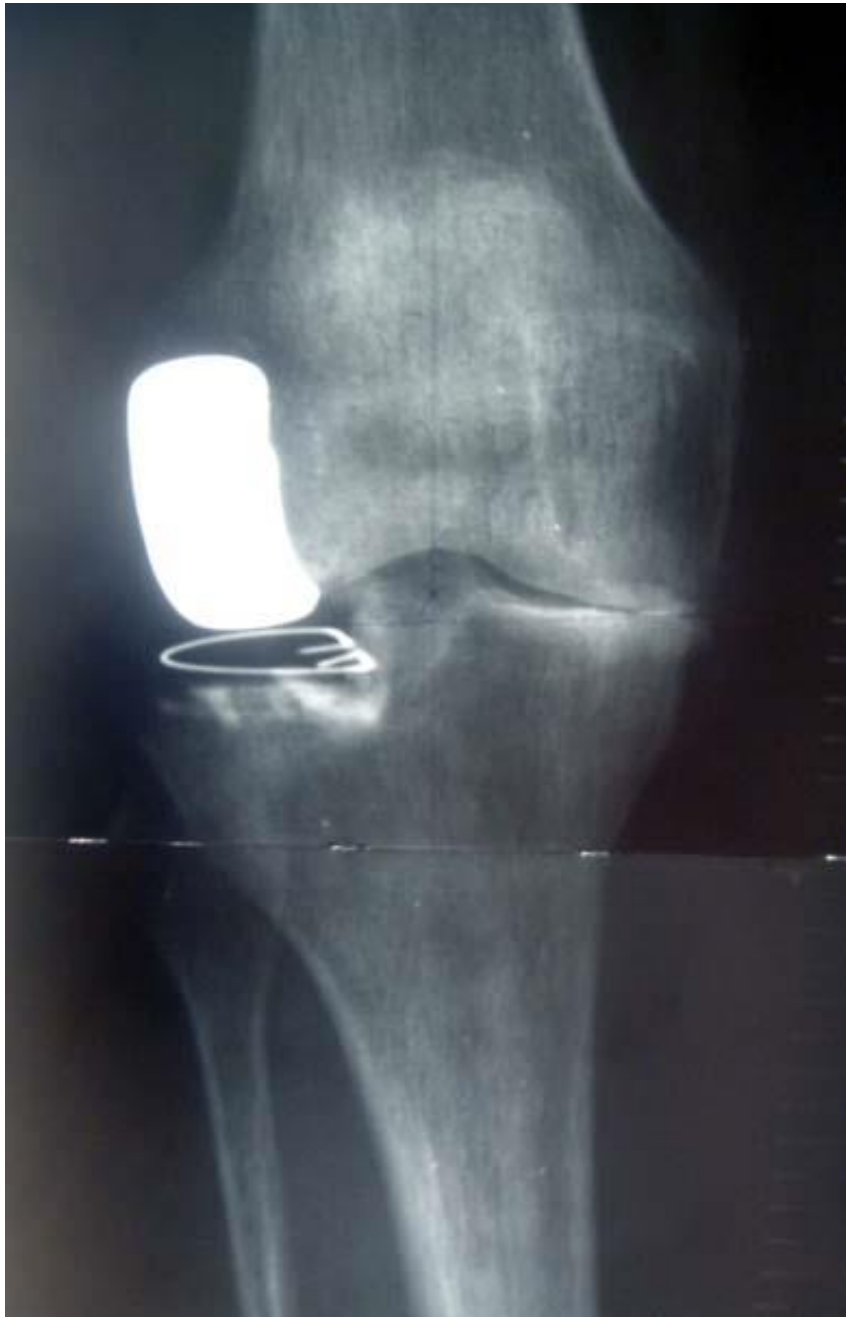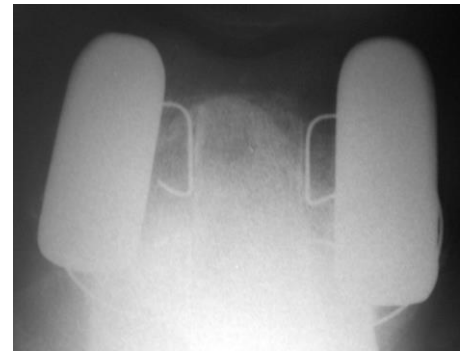
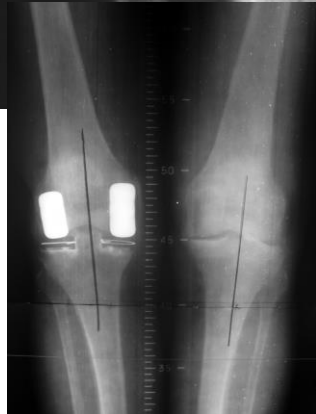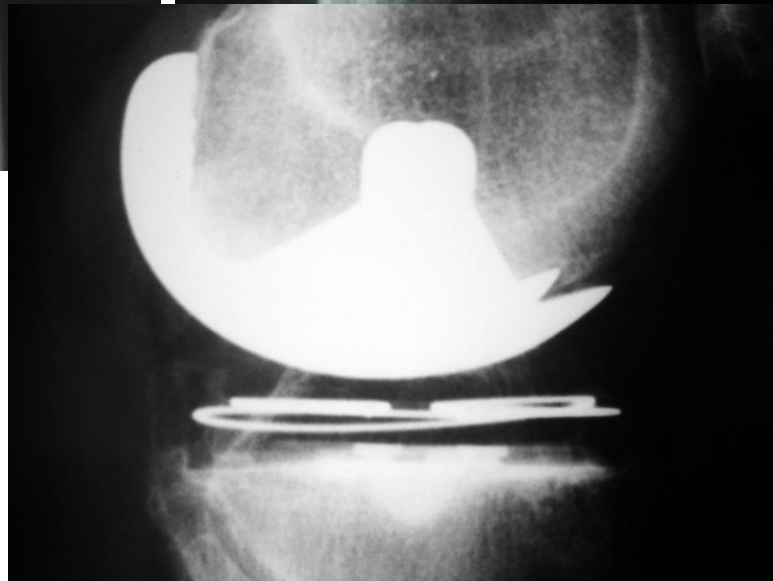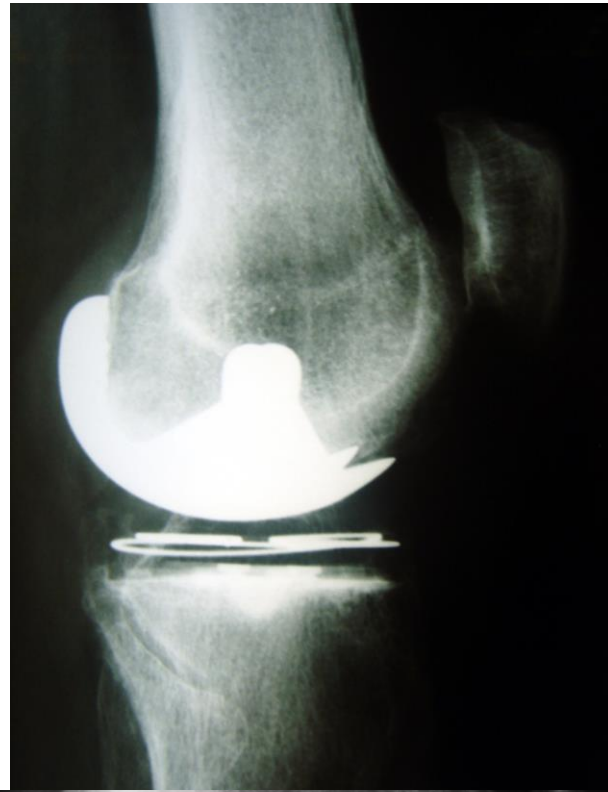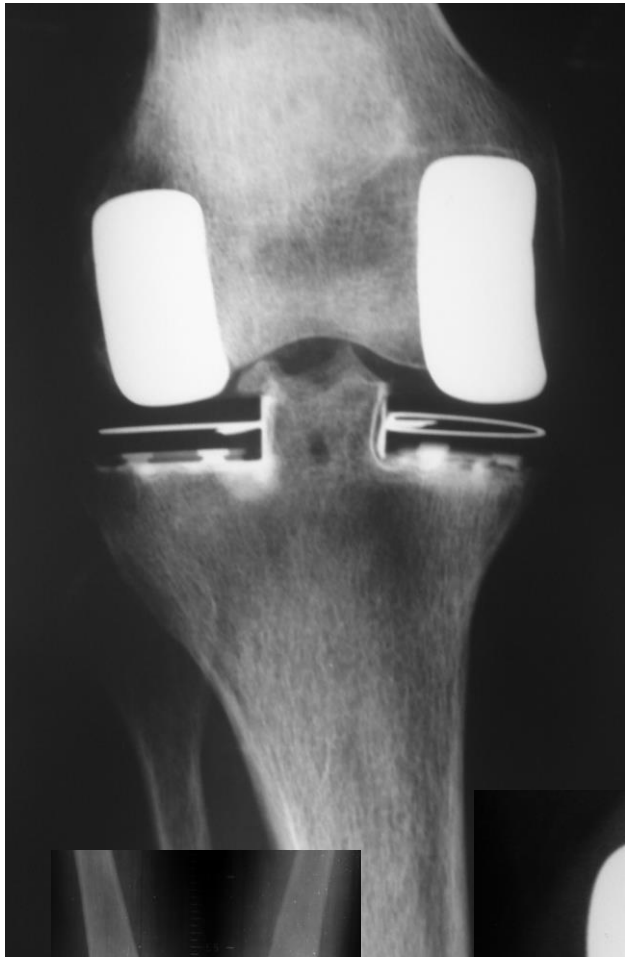
Lateral UNI + Facetectomy.

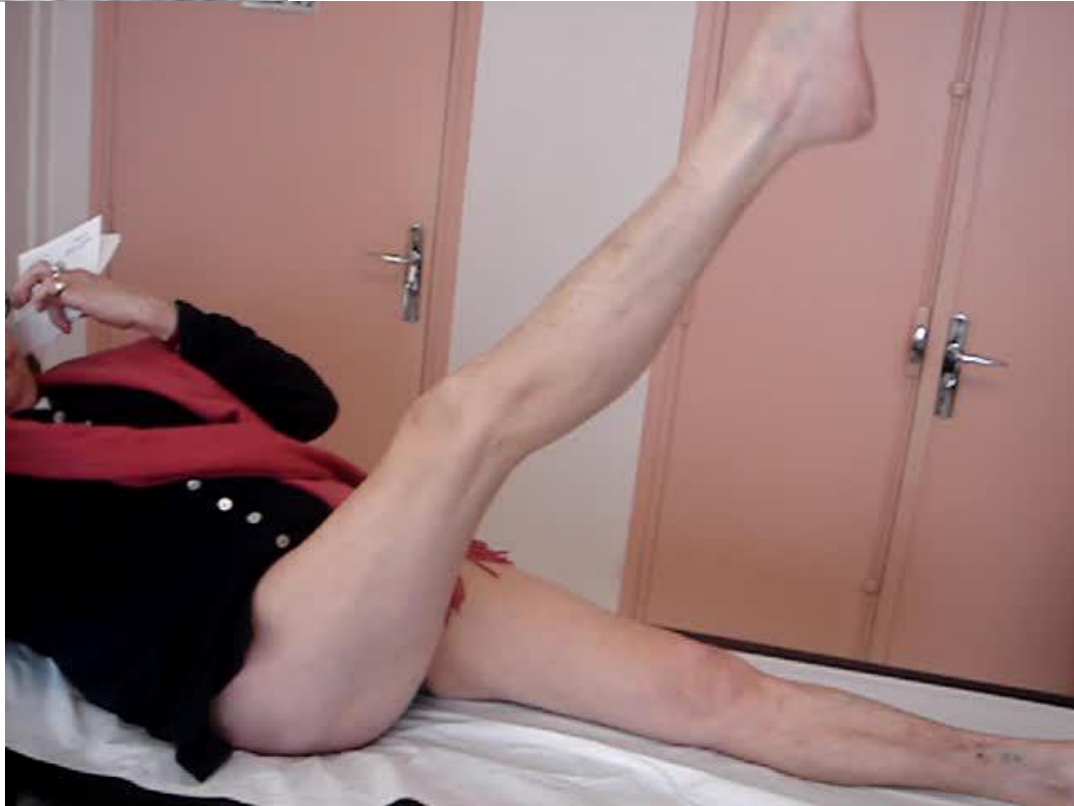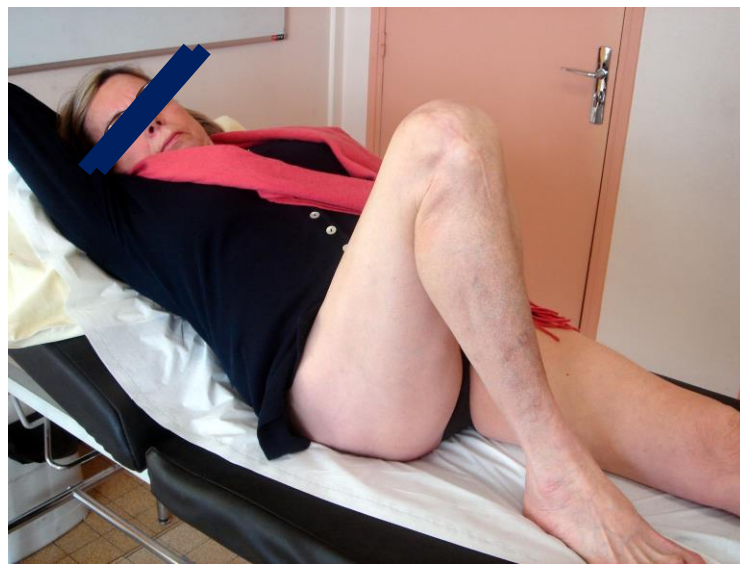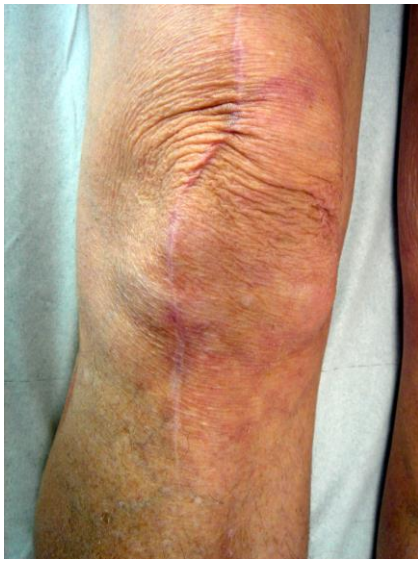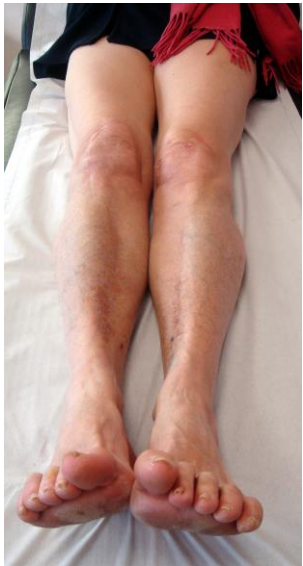Mrs DUB josephine, 92 Y.



Medial UNI + 12 y







MERCI